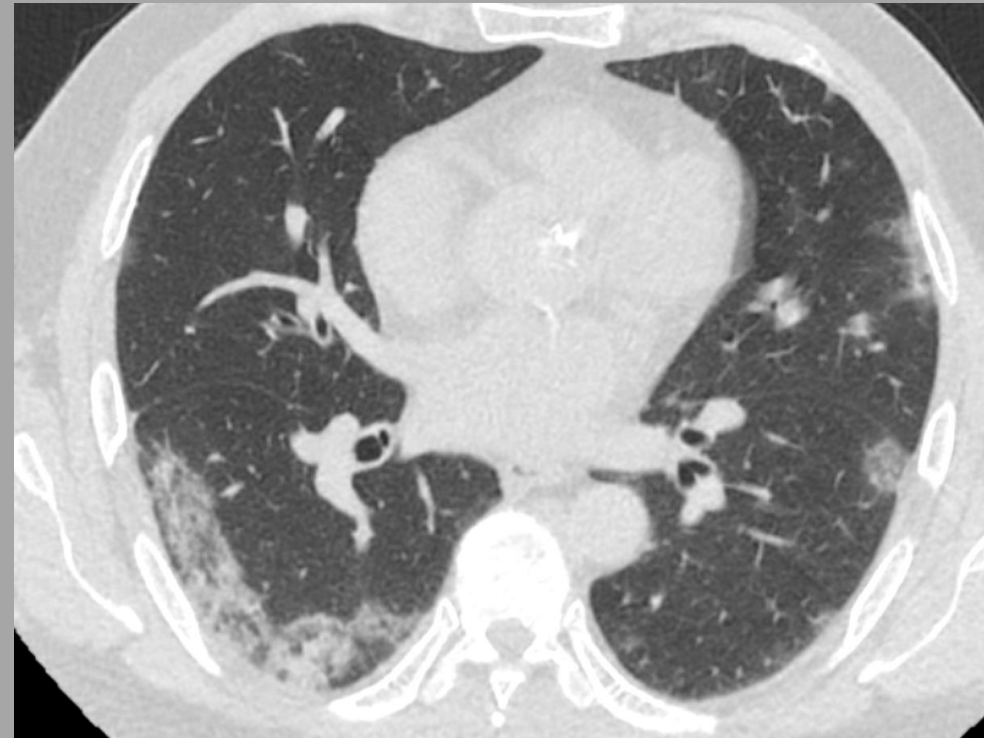
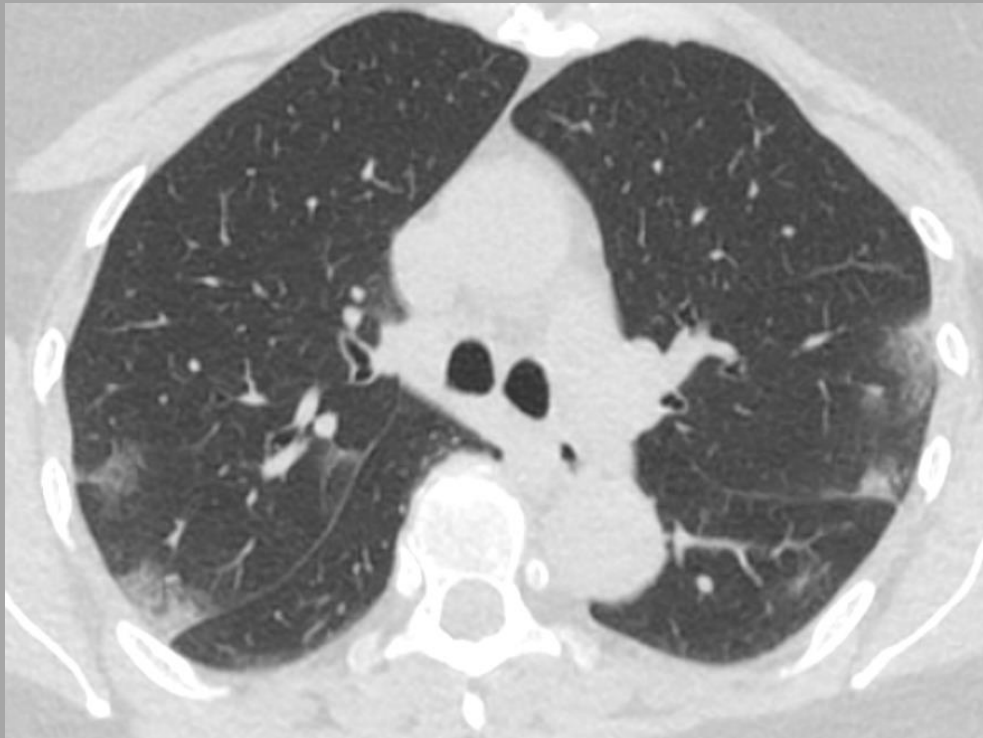

CT NÁLEZY V PLICNÍM PARENCHYMU U COVID-19

CT FINDINGS IN LUNG PARENCHYMA IN COVID-19

obrazový přehled/pictorial review



Jiří Ferda, Hynek Mírka, Jan Baxa, Petr Rajchman, Alena Vondráková, Jana Váchalová

FAKULTNÍ NEMOCNICE PLZEŇ /UNIVERSITY HOSPITAL PILSEN- CZECH REPUBLIC

COVID-19 – obecné CT příznaky

COVID-19 – general CT symptoms

Periferně uložené opacity typu mléčného skla, někdy velmi měkké;
příznak rozpouštěného cukru – unikání infiltrátu do periferie; často
kontakt s viscerální jemně zesílenou pleurou (včetně interlobia);
přibývání infiltrátů kaudálním směrem

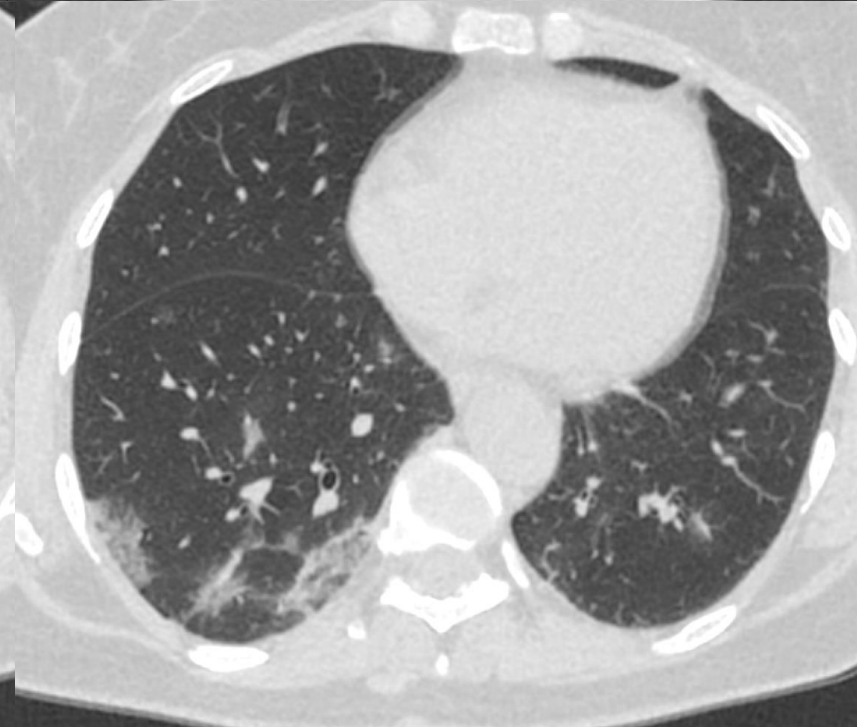
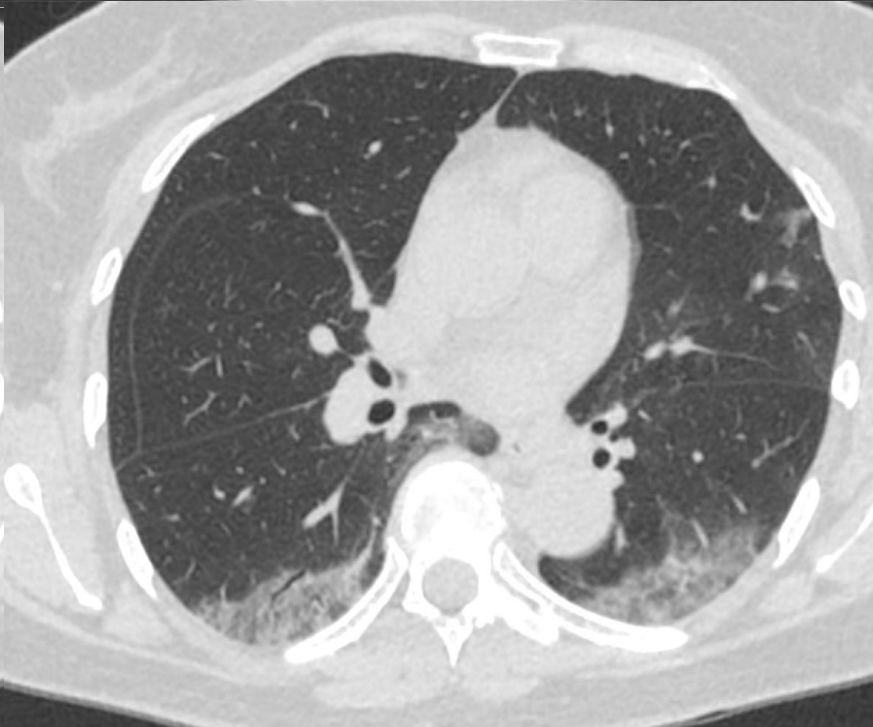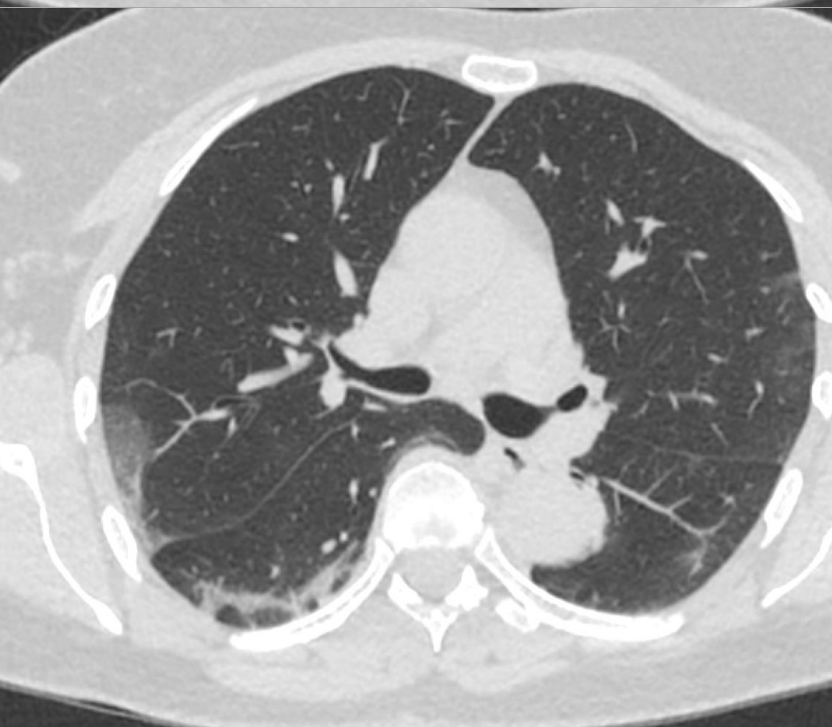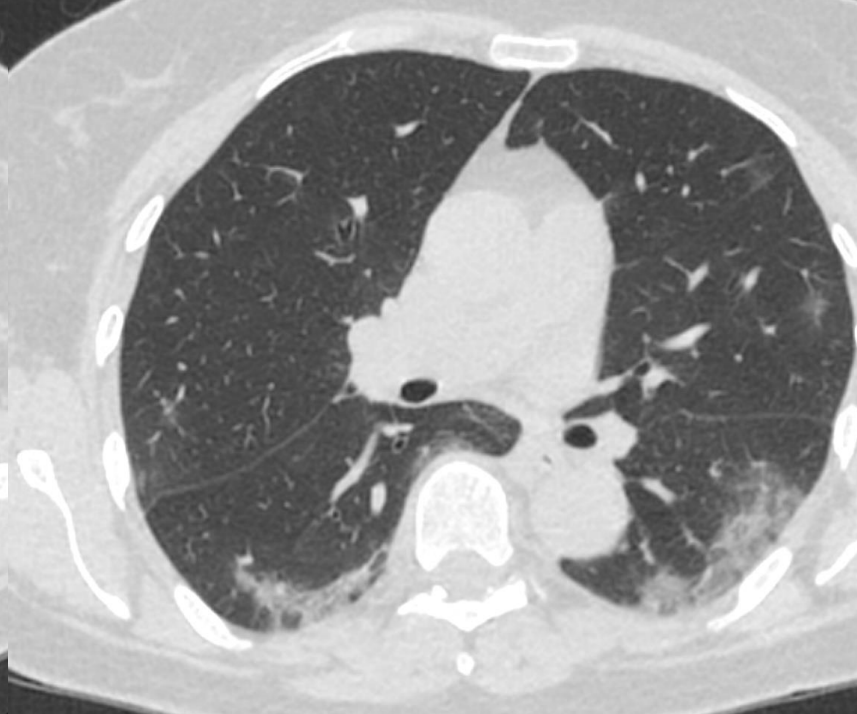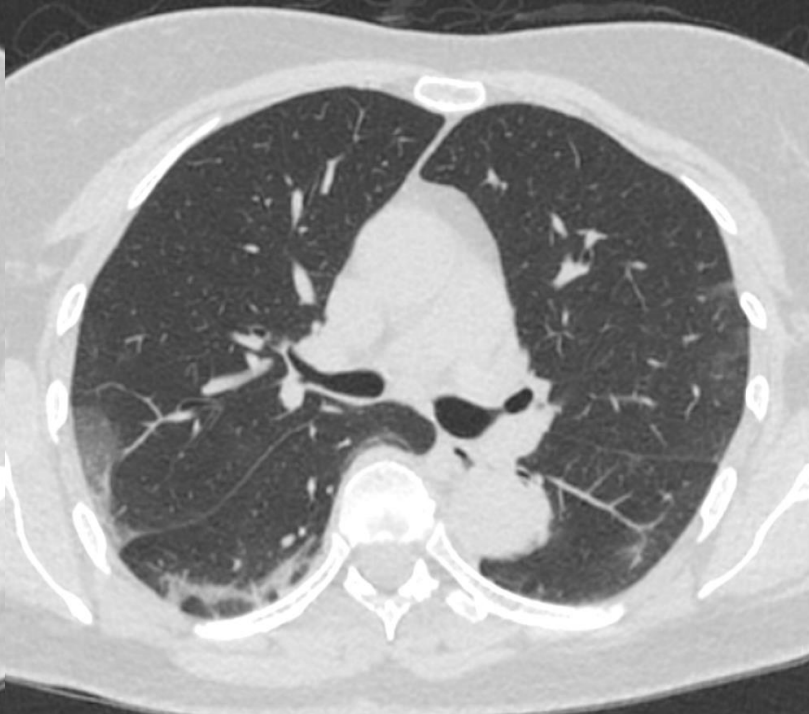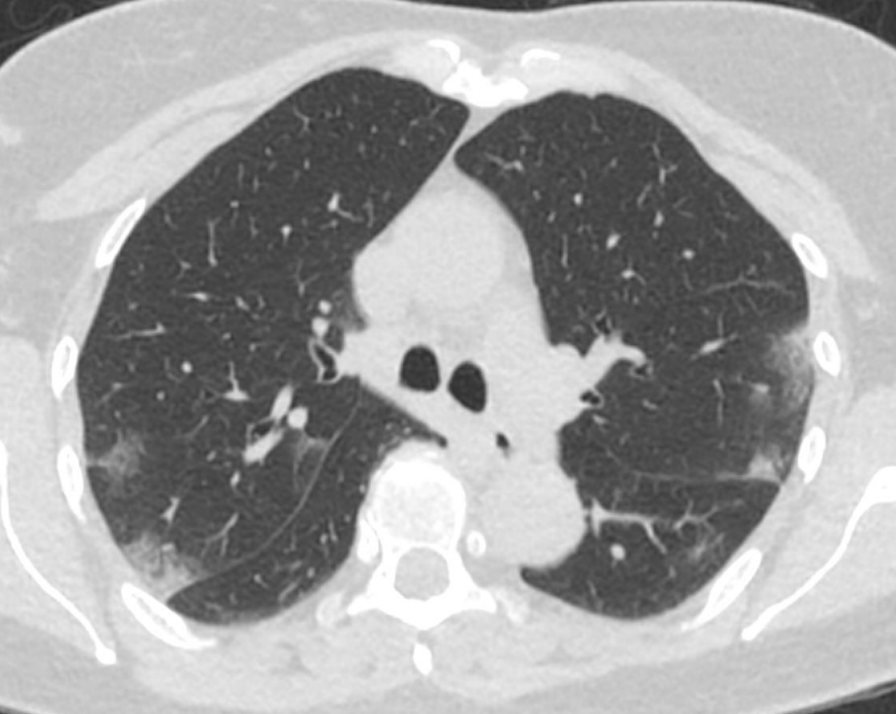**Ground glass opacities with peripheral distribution, some very soft;
sign of the dissolving sugar – peripherally escaping infiltration; often
contact with tiny thickened visceral pleura (including interlobium);
increasing number of the infiltrates in caudal direction**

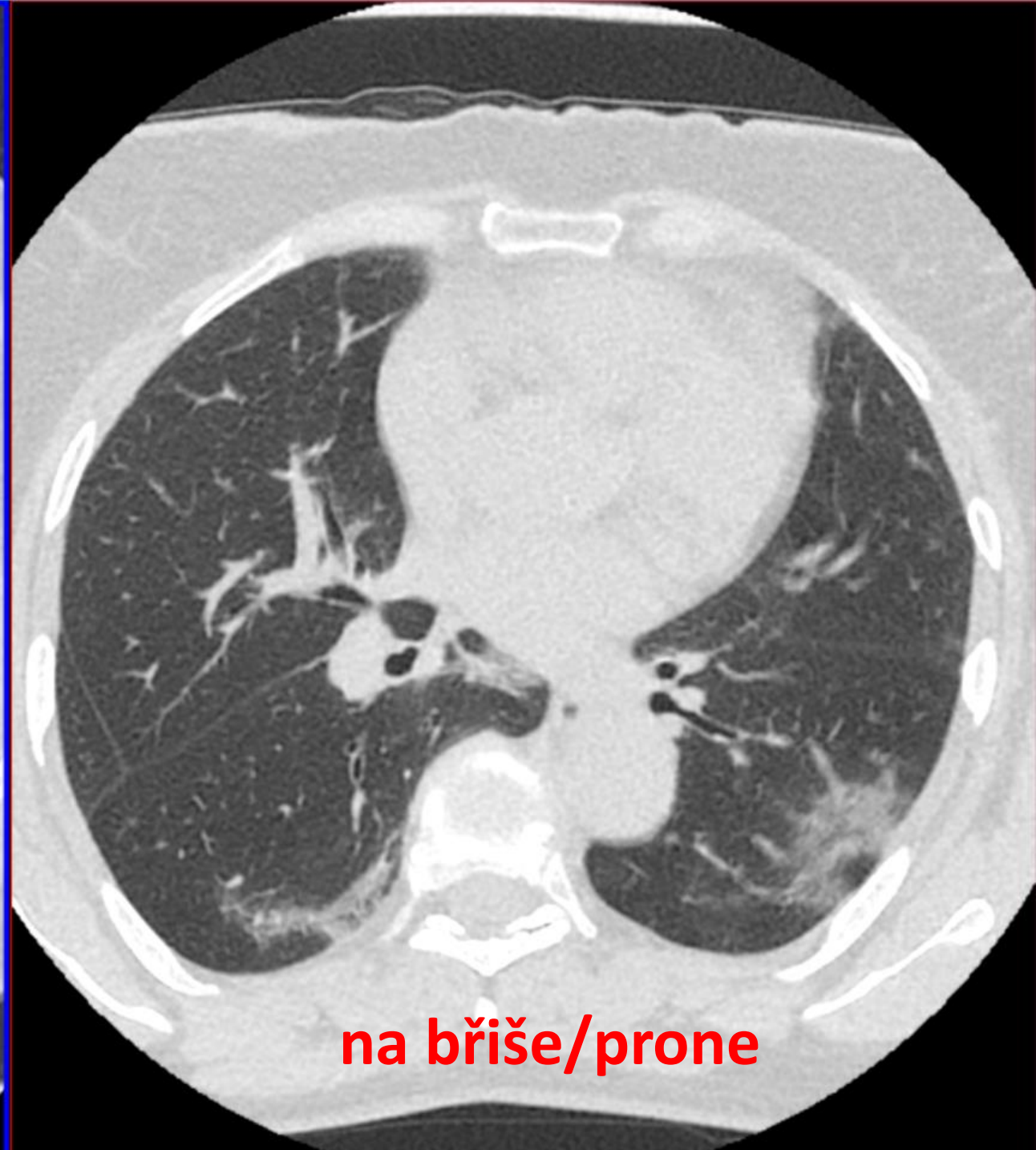
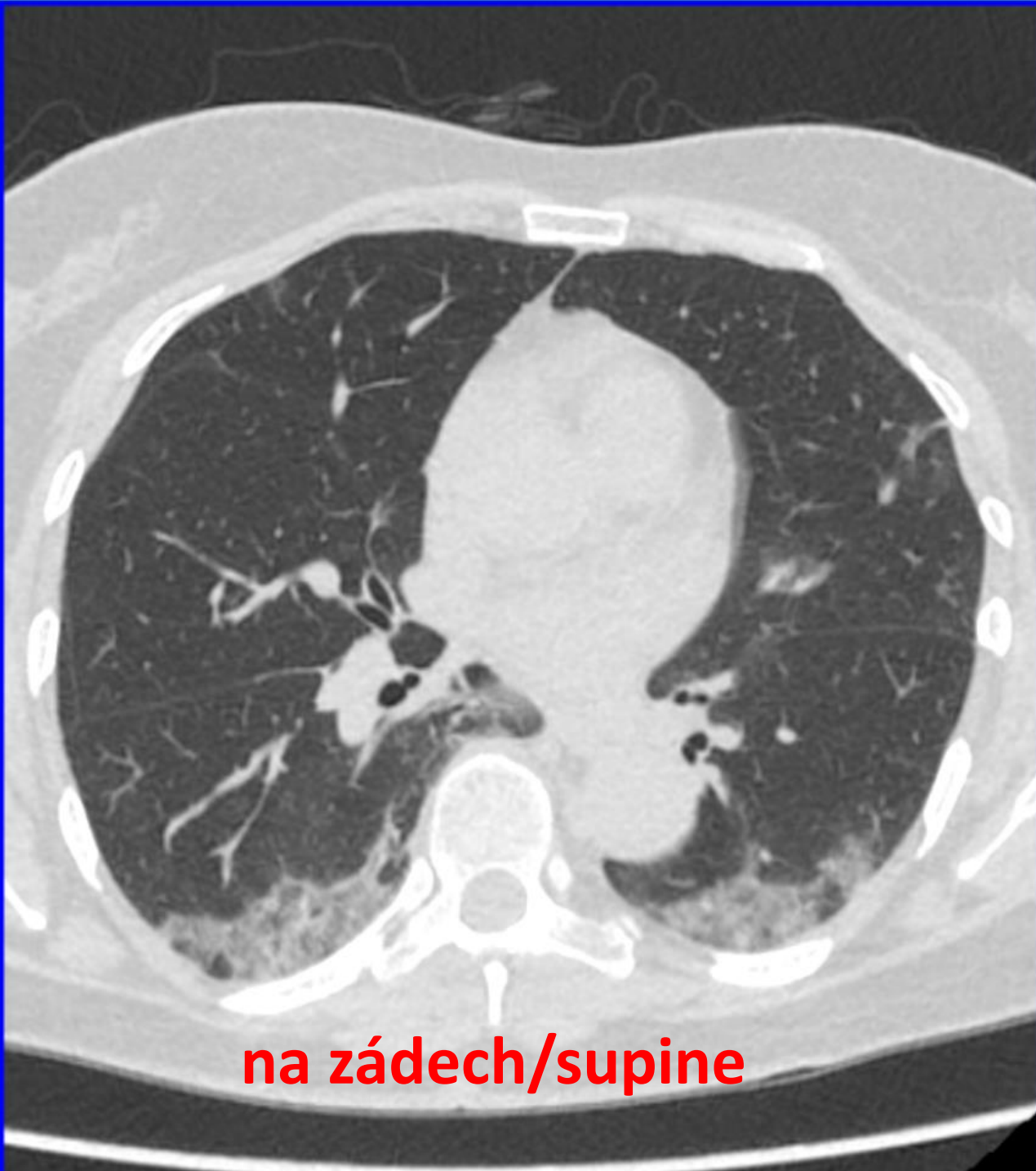
KASUISTIKA č. 1 - COVID-19

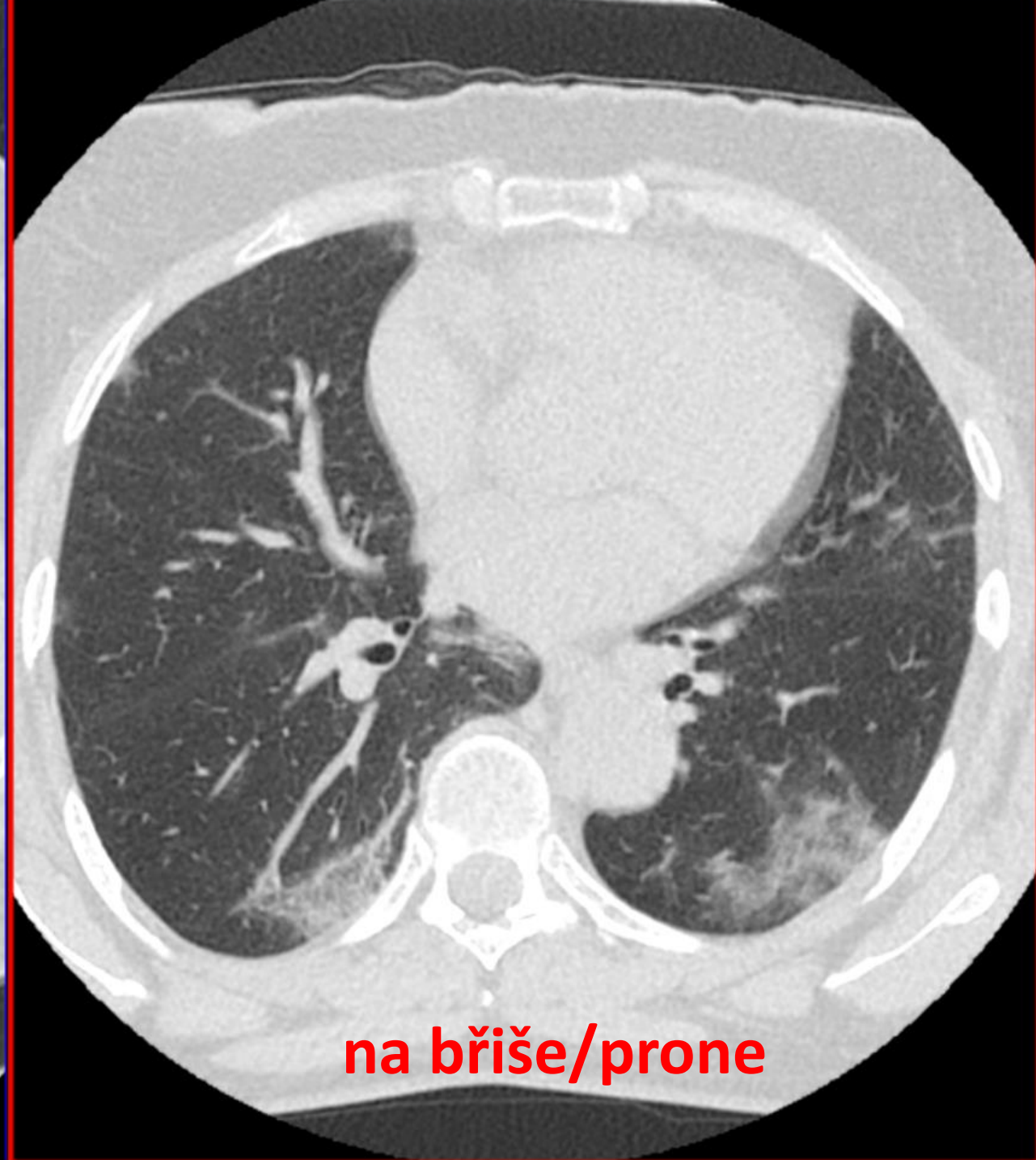
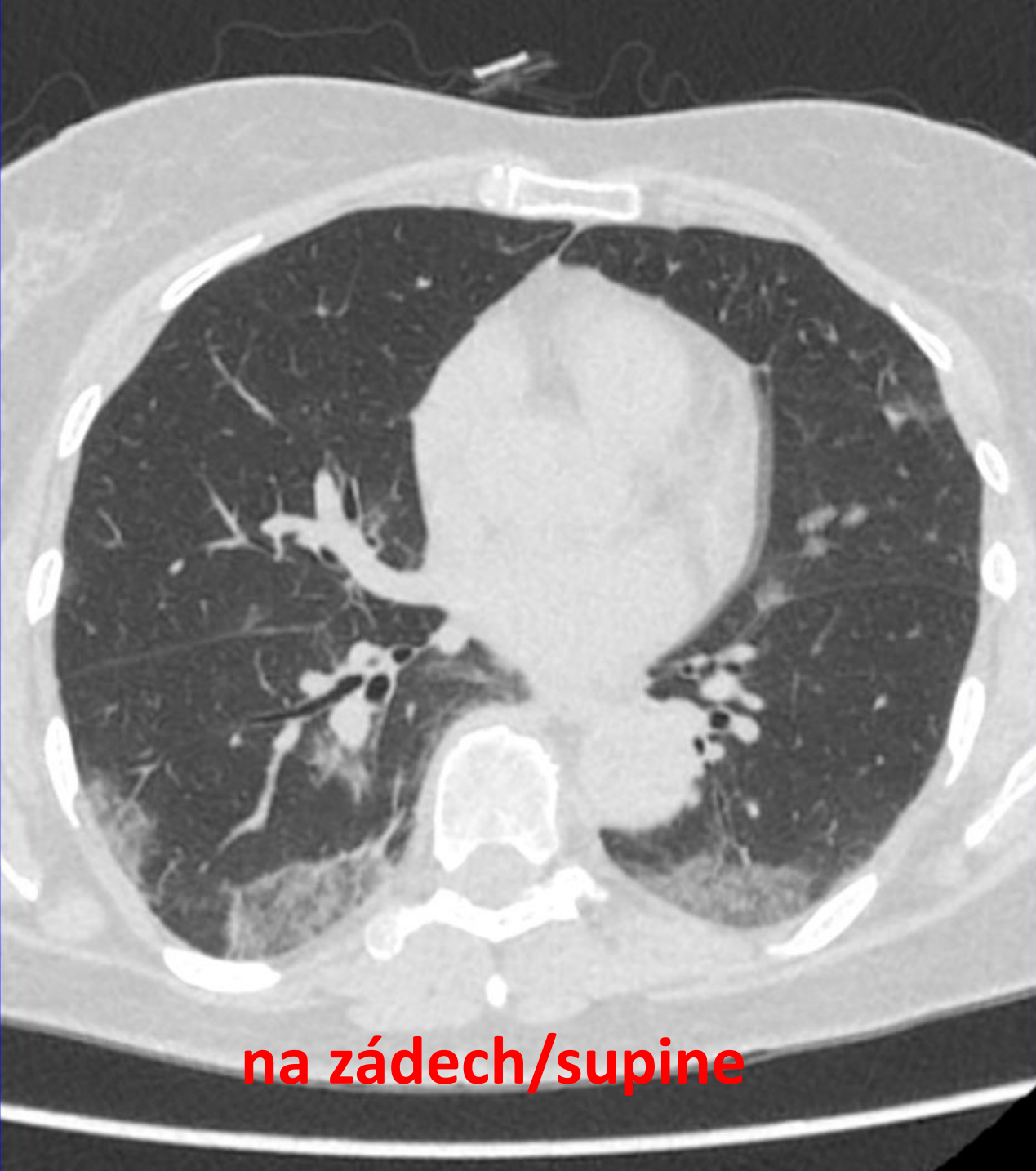
CASE No. 1 - COVID-19

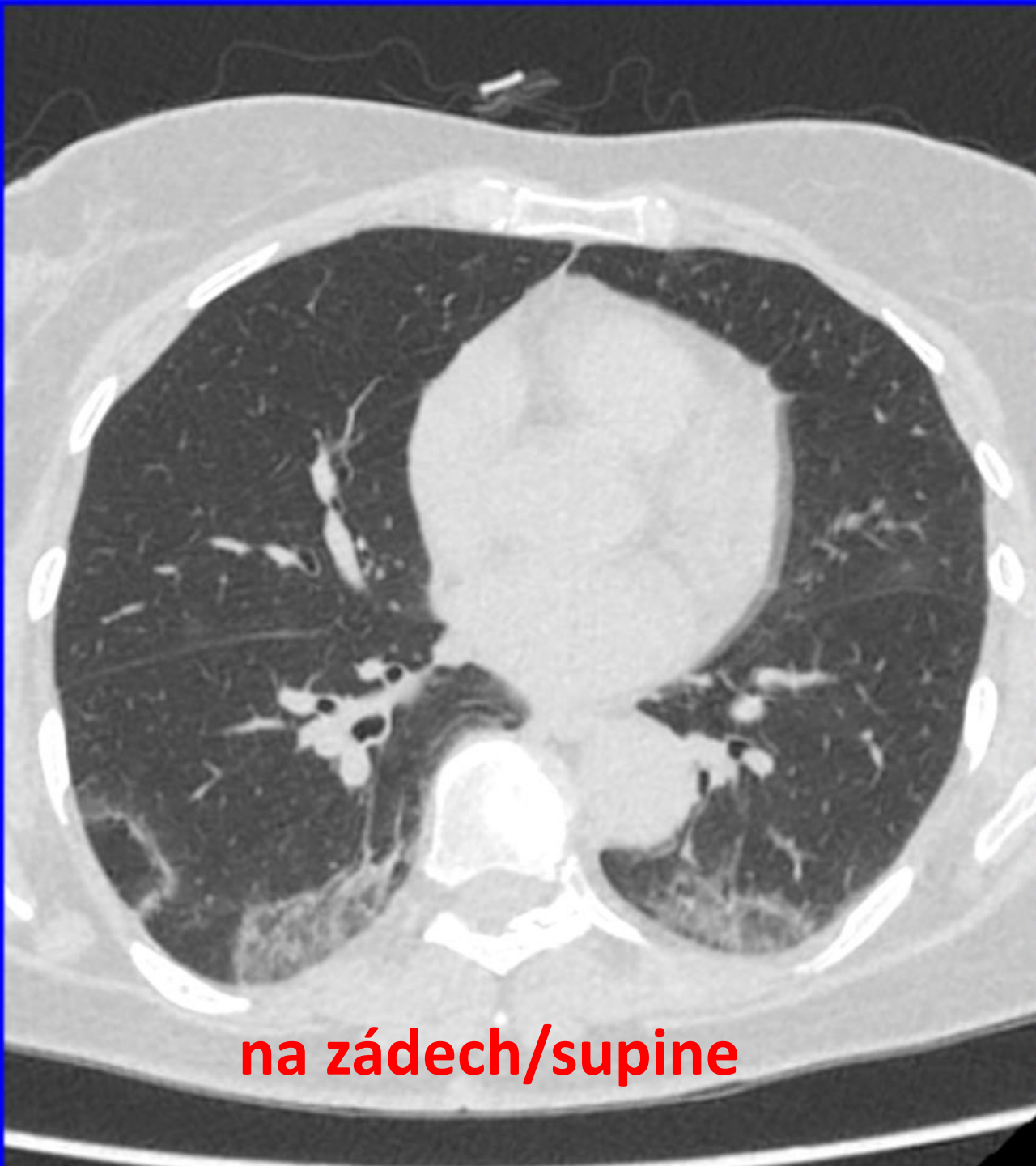
žena 58 let horečky až 39,2 st. C, třesavka, kašel, myalgie,
bolesti hlavy, bolesti na hrudi, prodavačka, klientela z
Německa, bez cestovatelské anamnézy, RT-PCR SARS-CoV-2
pozitivní

**female 58 yo, fever up to 39.2 Celsius gr., coughing, myalgia,
shivering, headache, chest pain, clothing shop assistant,
German clients only, no travelers history, RT-PCR SARS-CoV-2
positive**

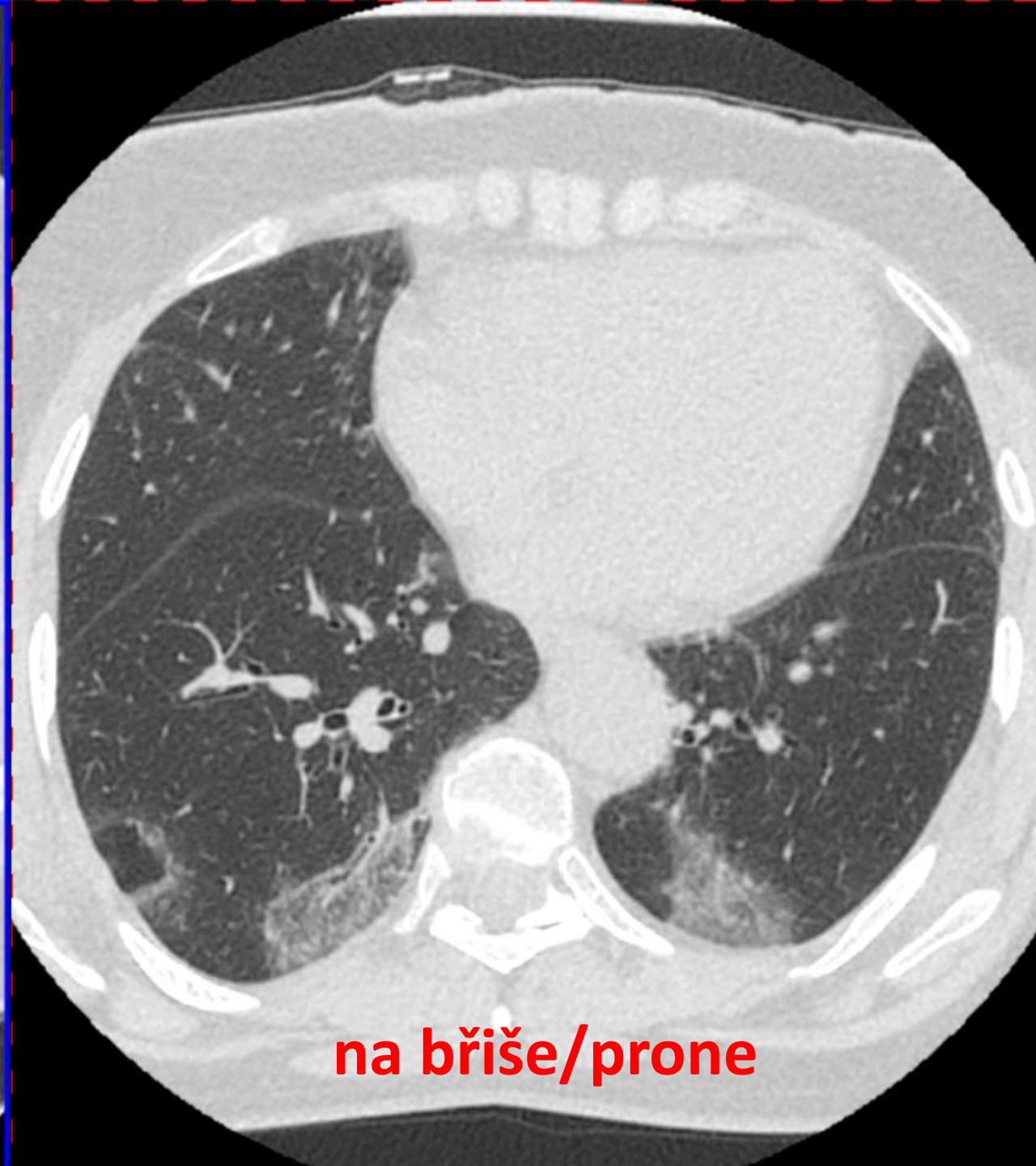




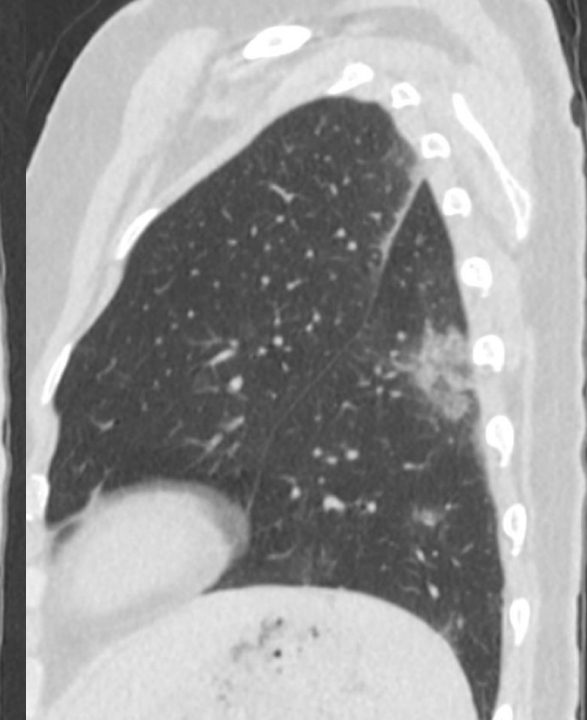
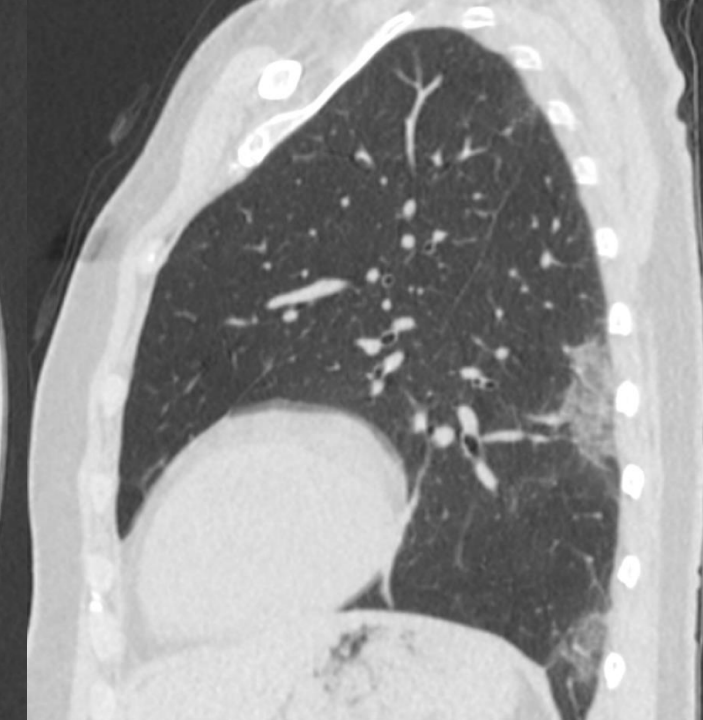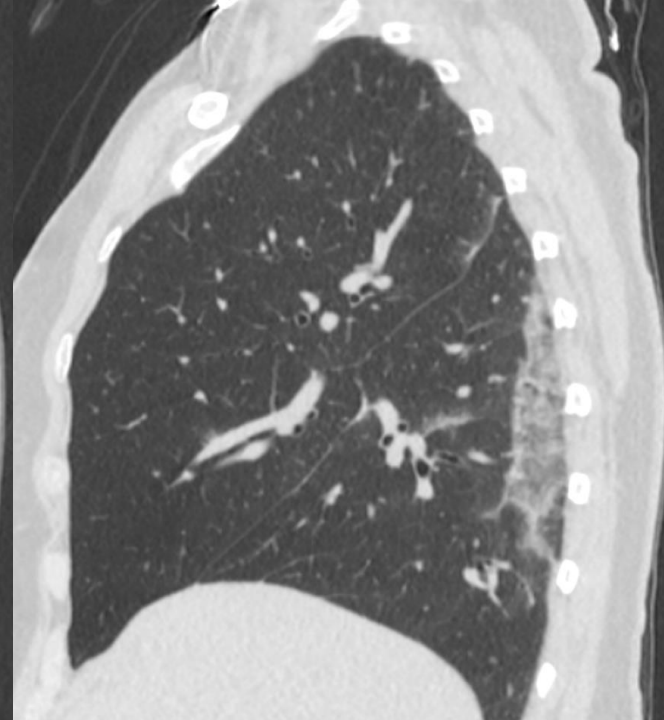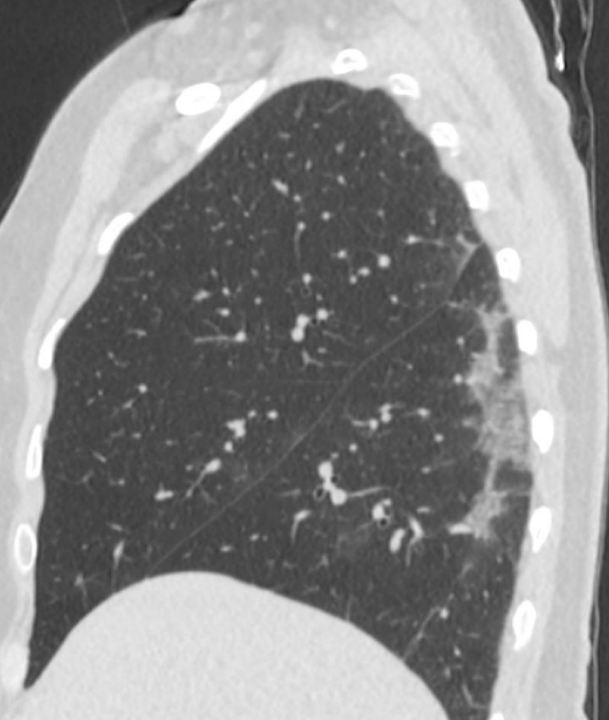
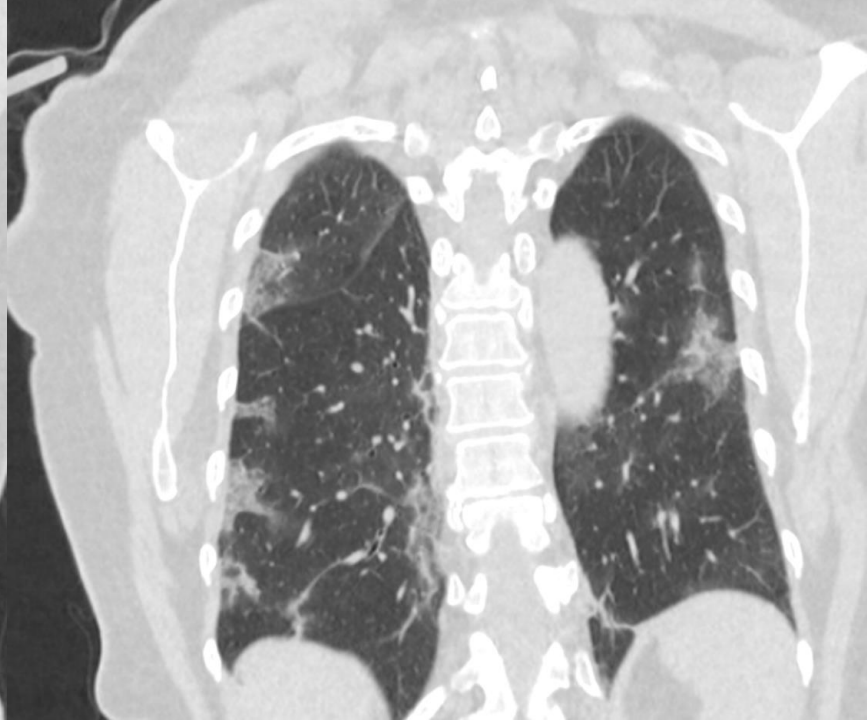


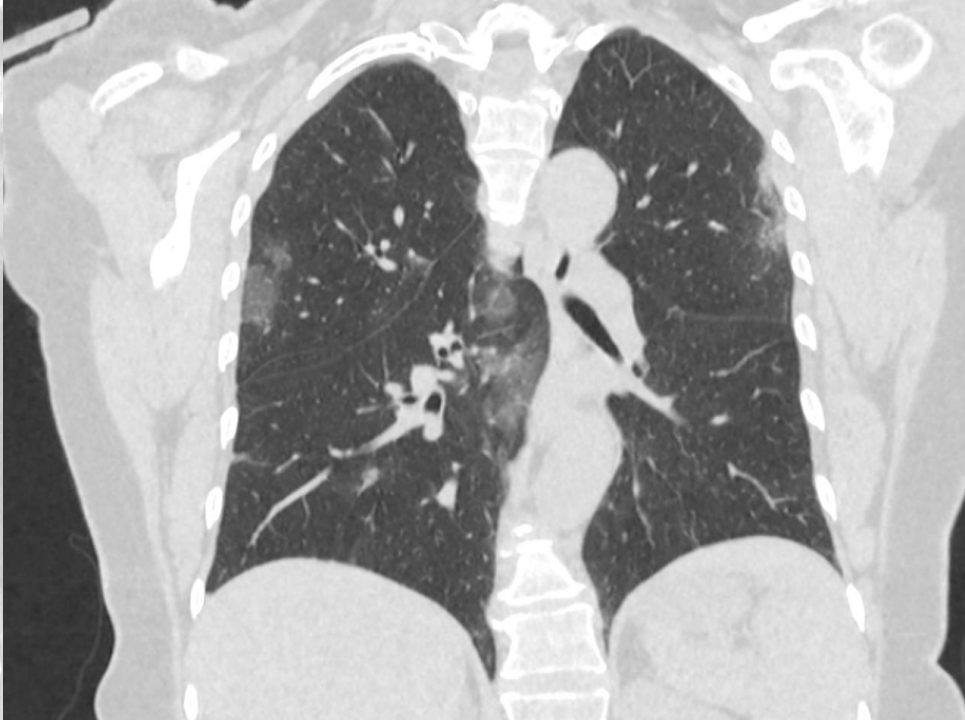
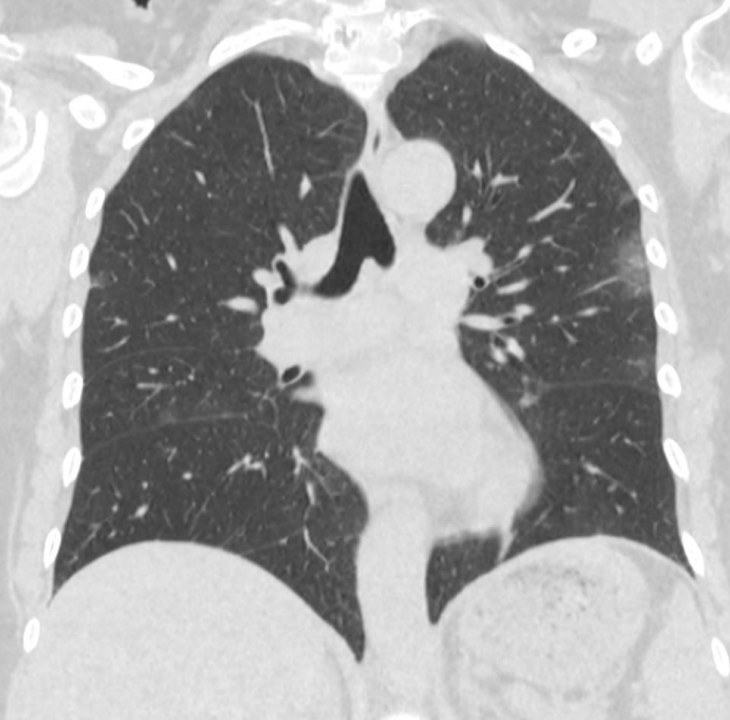
na zádech/supine



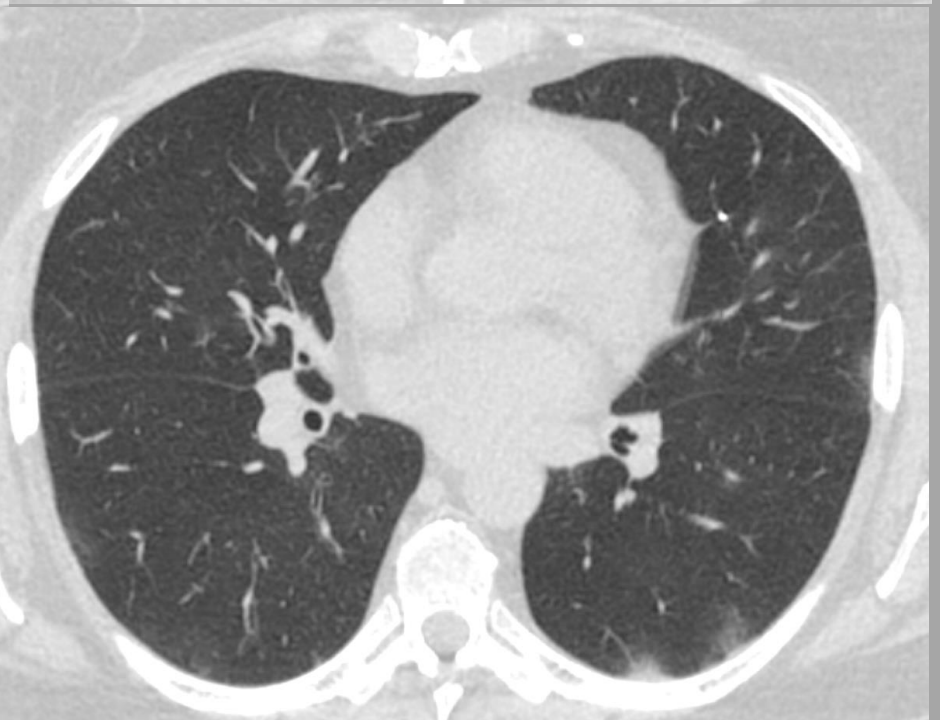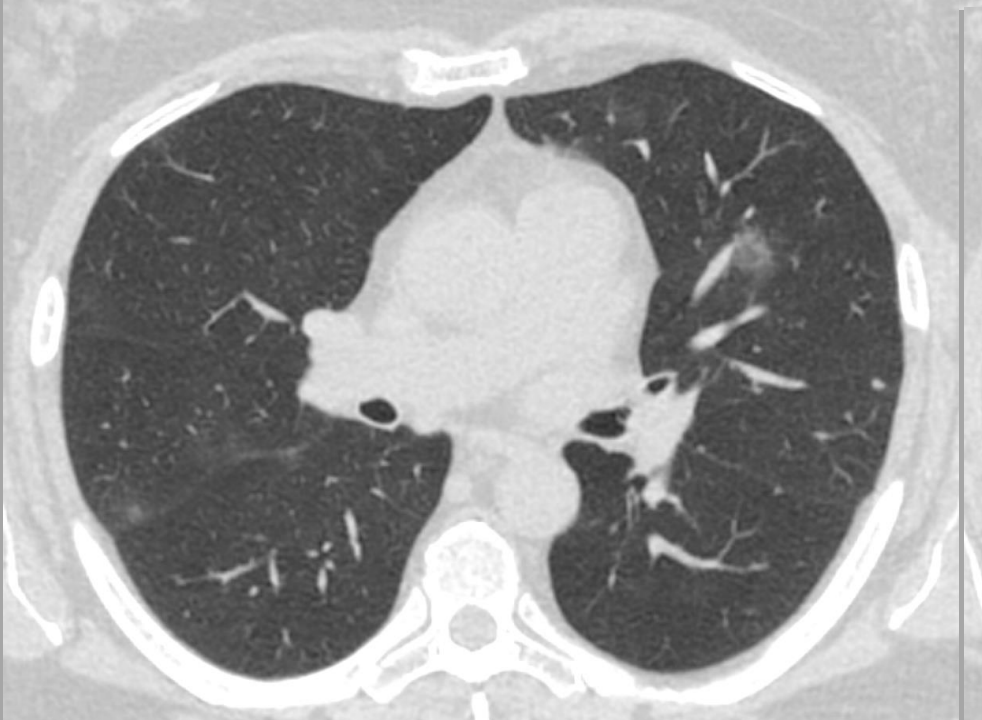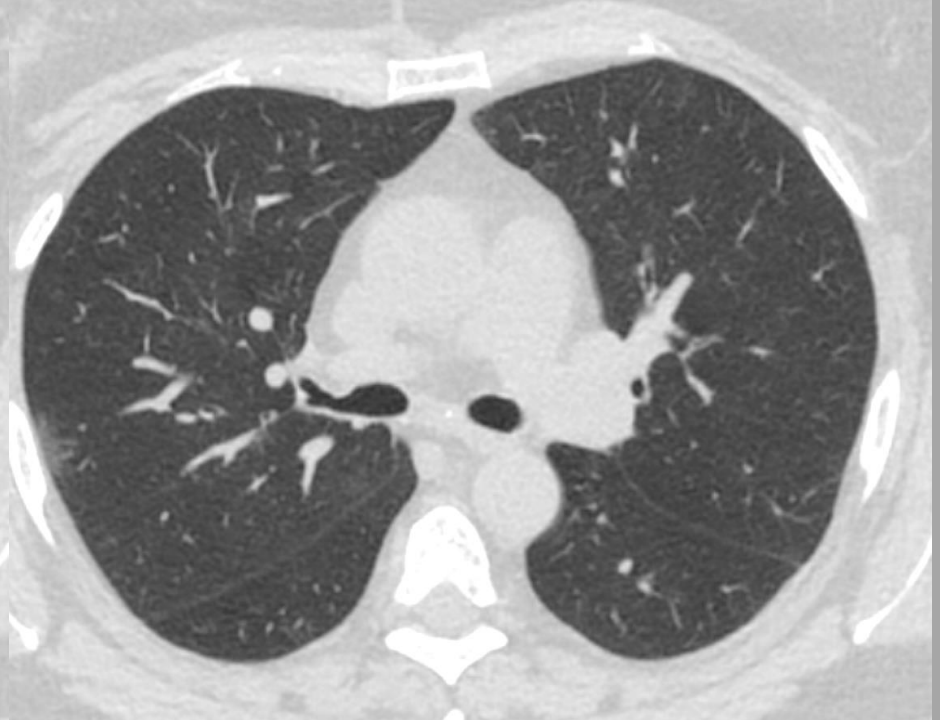
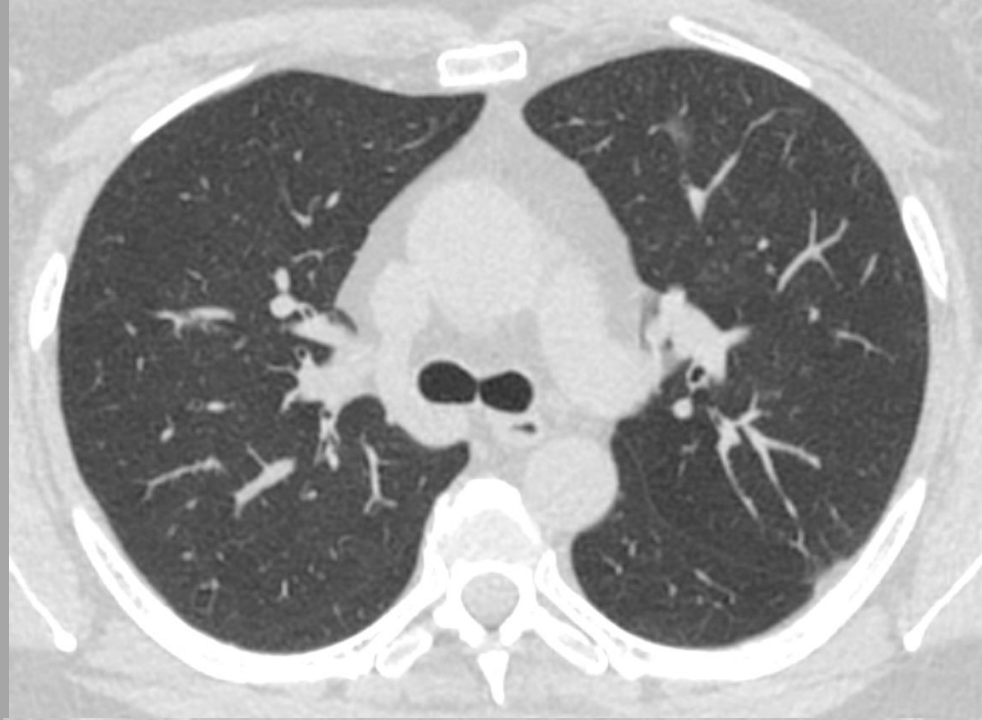na bříše/prone



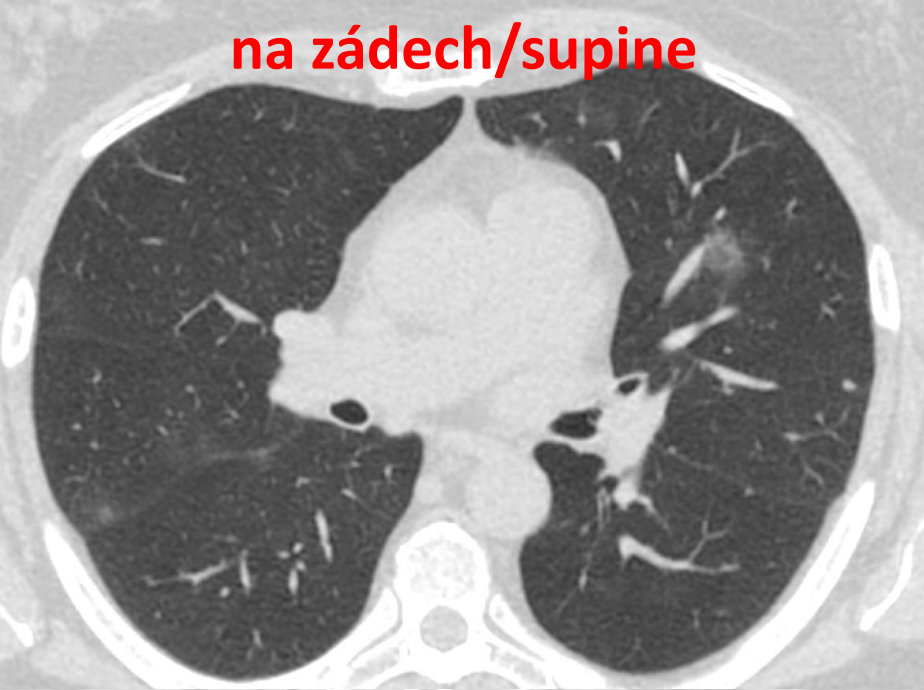KASUISTIKA č. 2 - COVID-19

CASE No. 2 - COVID-19

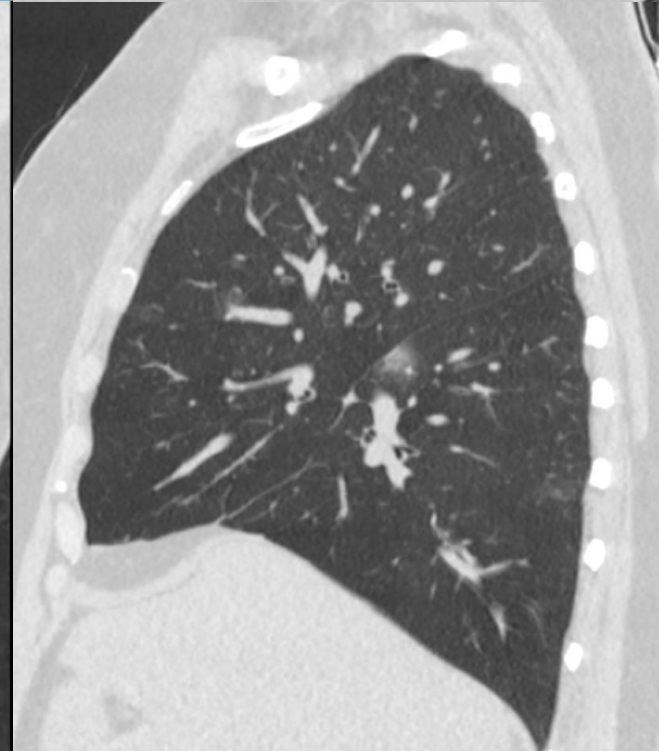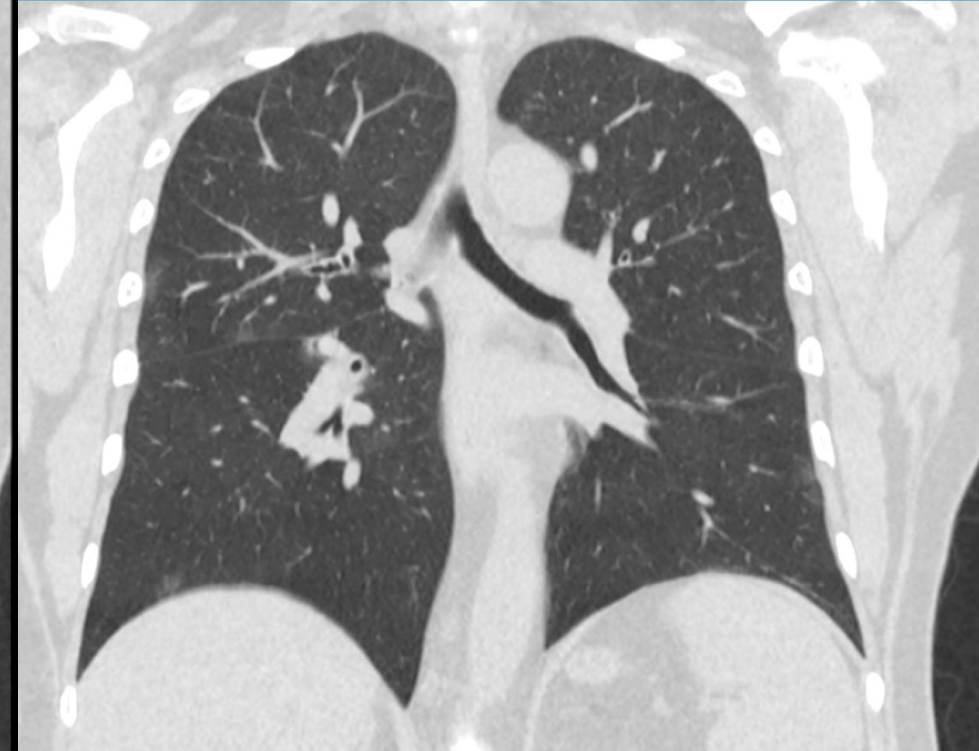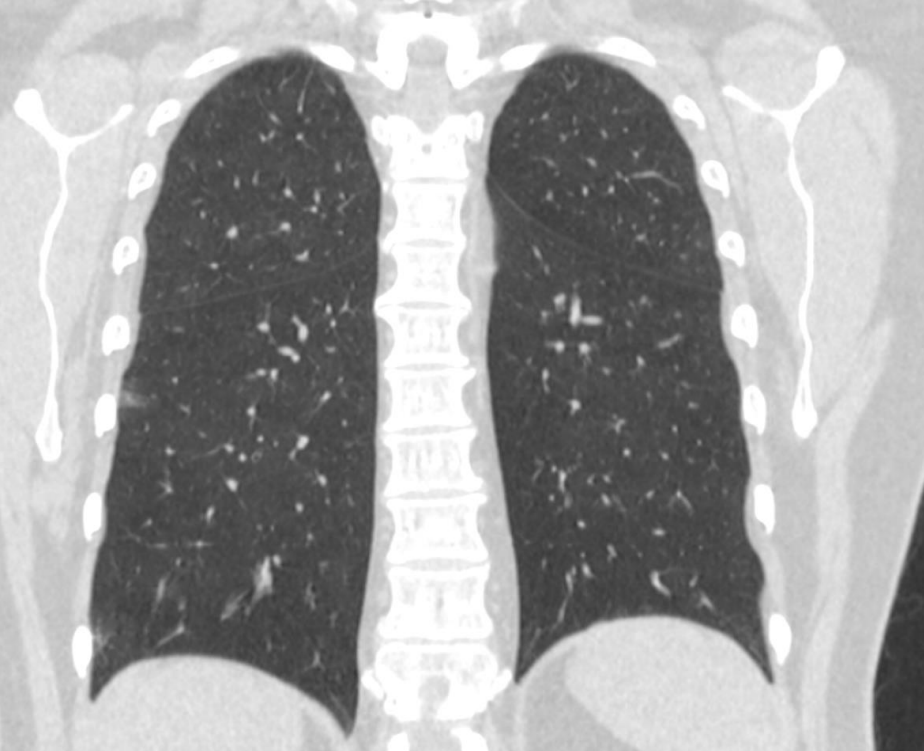
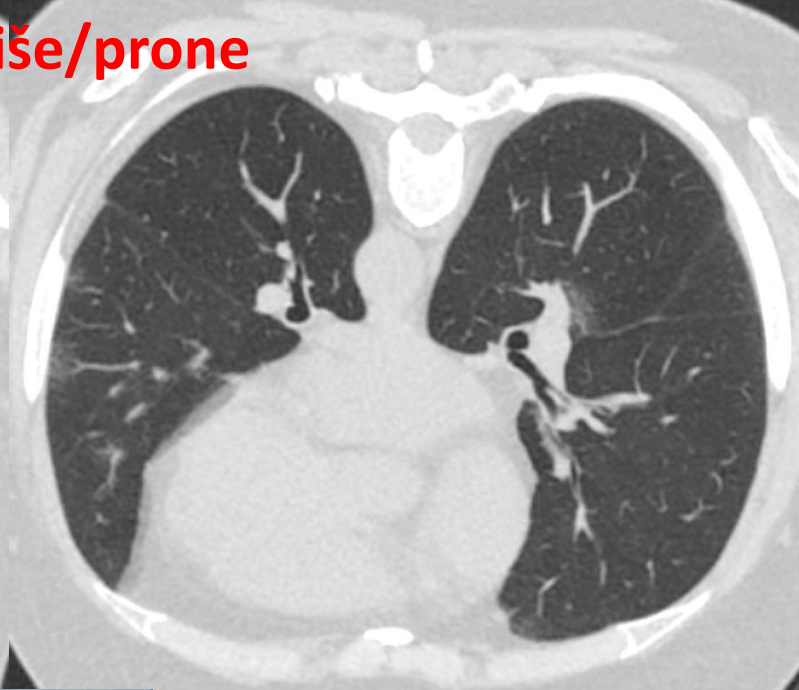
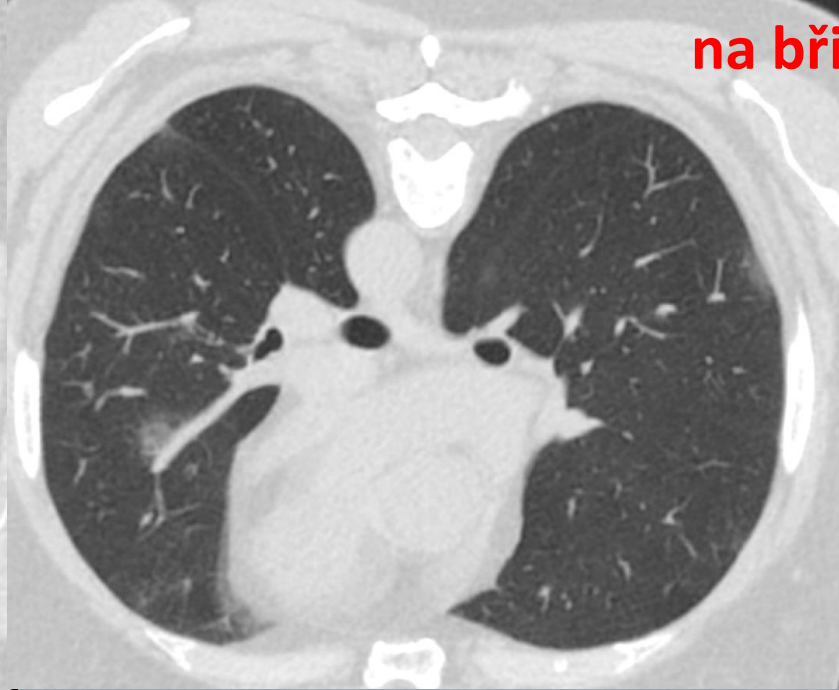
žena 61 let, 4 dny pacientka intermitentně subfebrilní,
dráždivý kašel, RT-PCR SARS-CoV-2 pozitivní
female 61 year old, 4 days intermittent subfebrile,
irritative coughing, RT-PCR SARS-CoV-2 positive

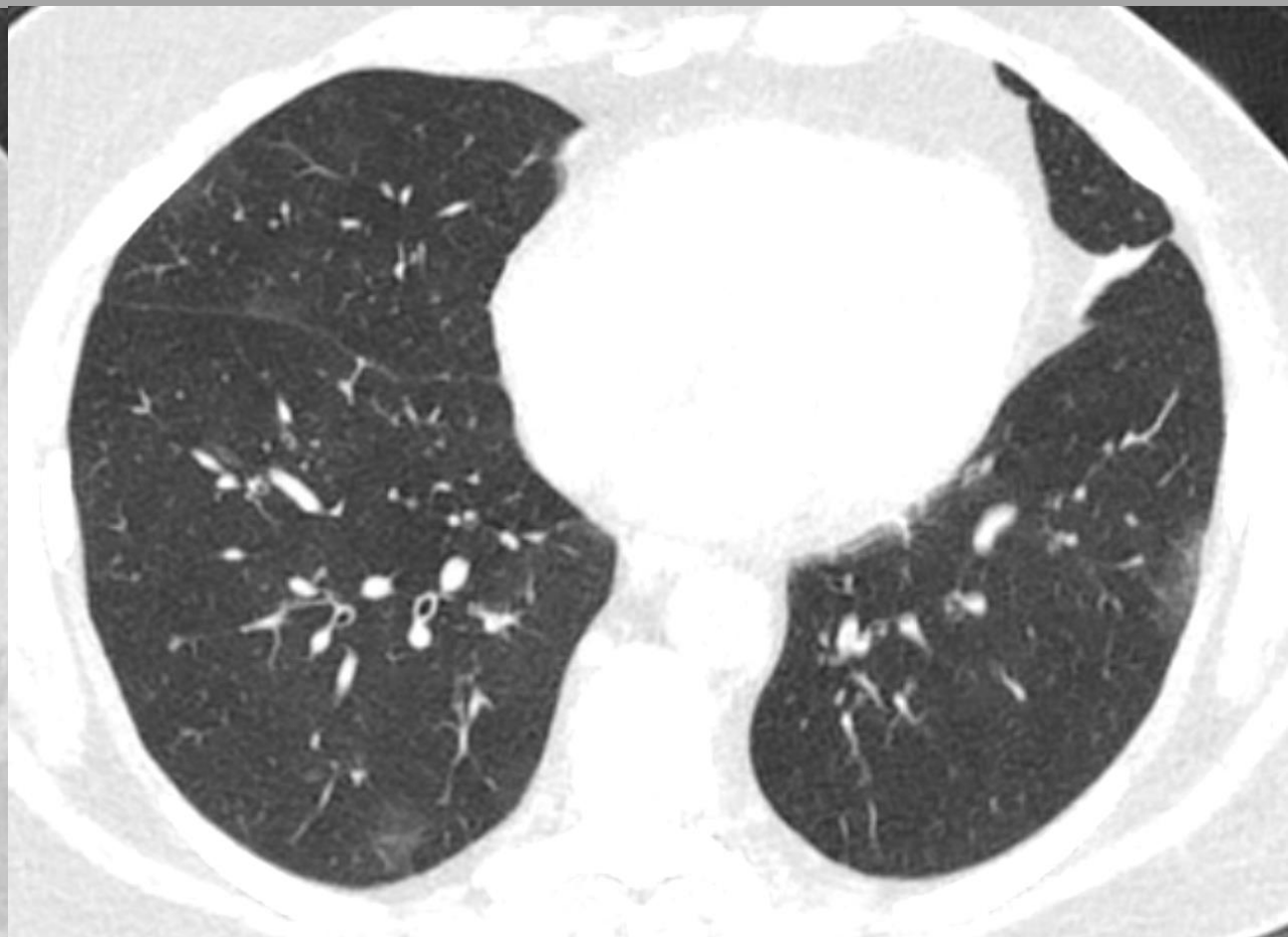
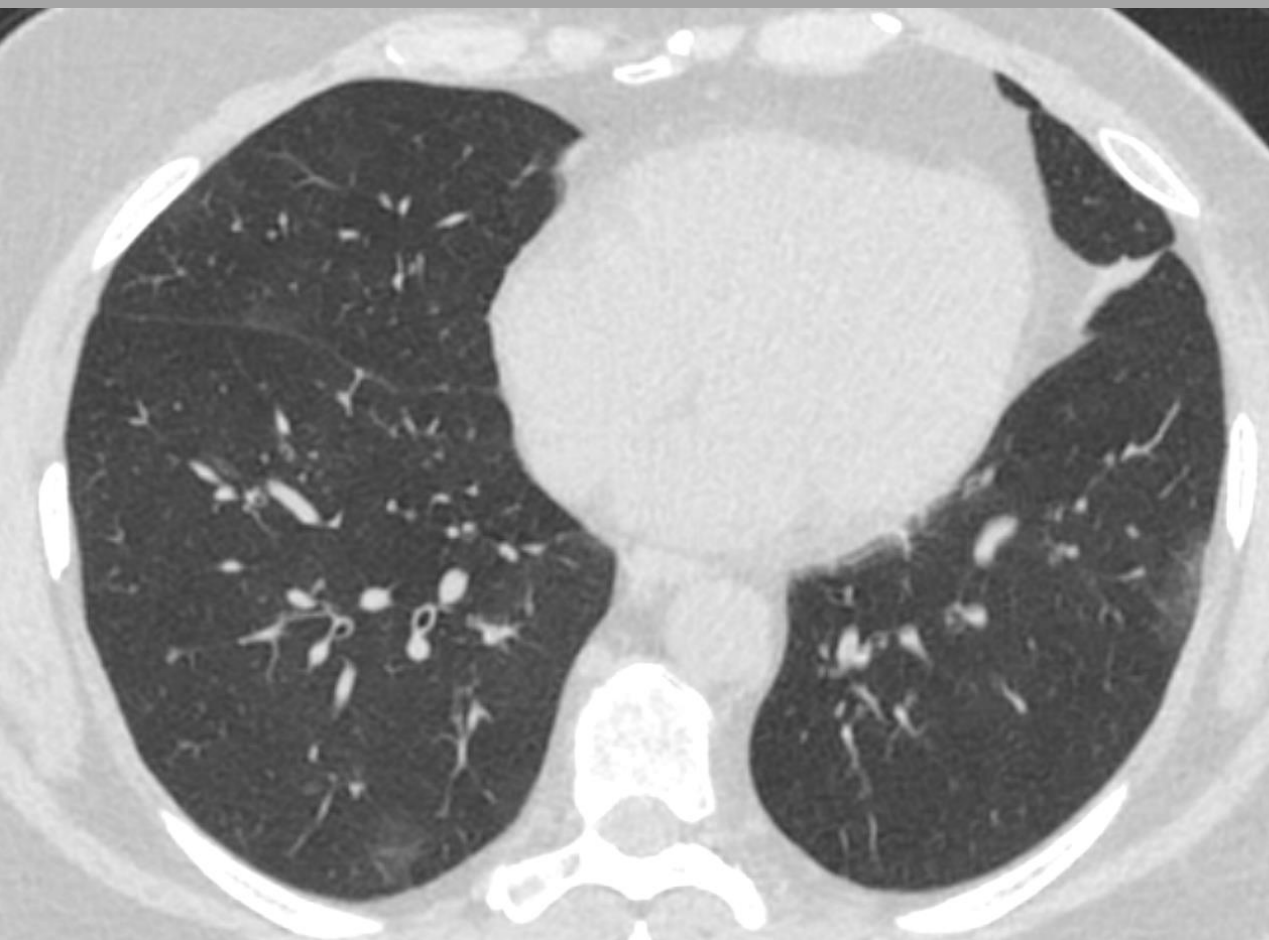

na zádech/supine



na břiše/prone



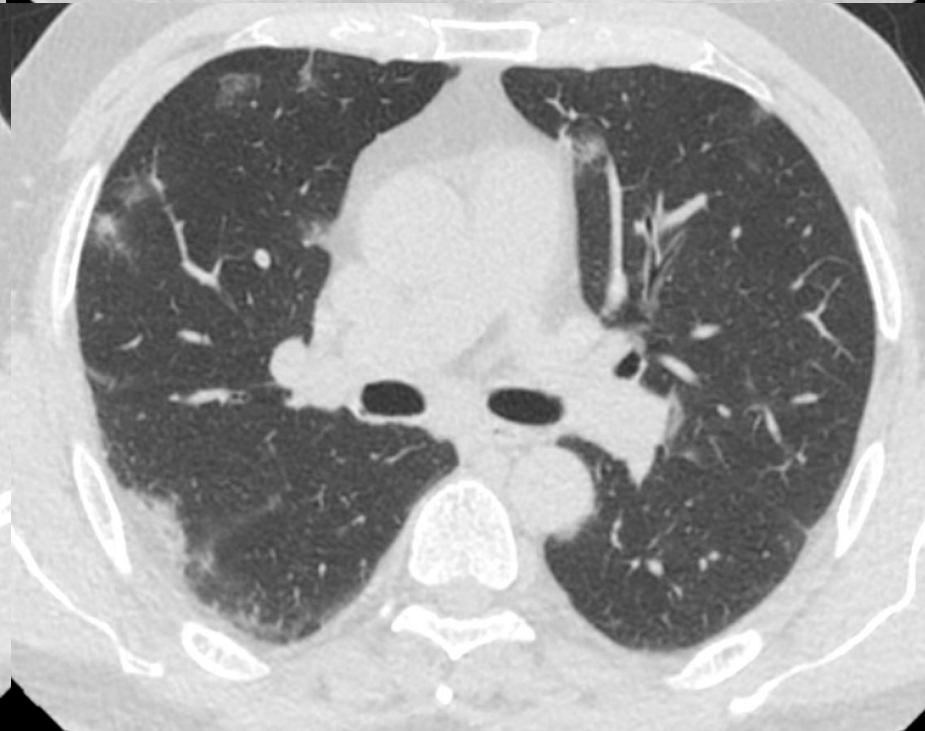
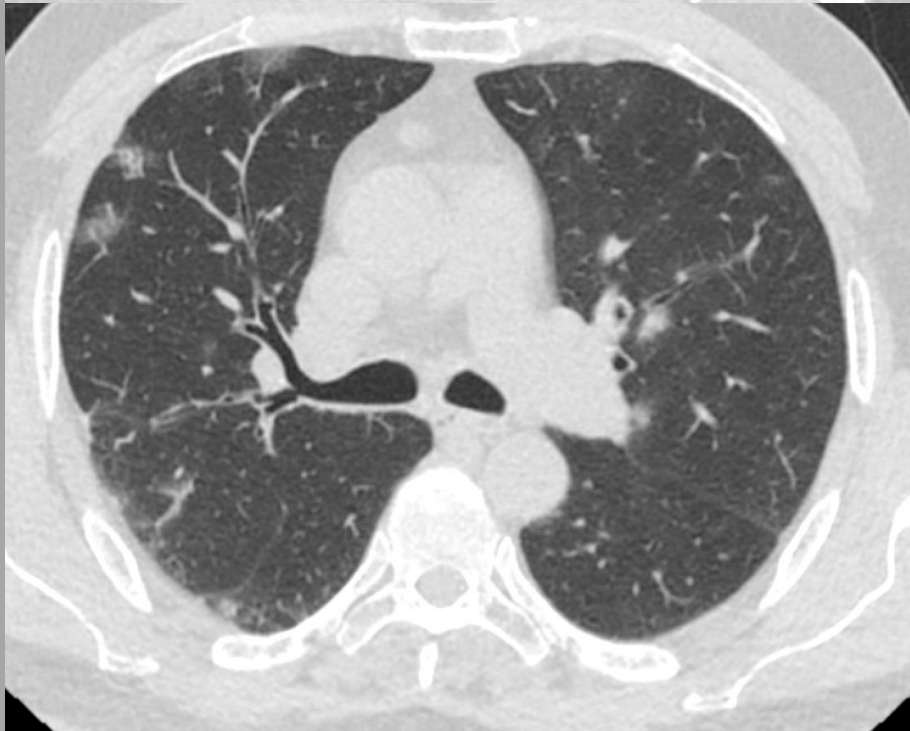
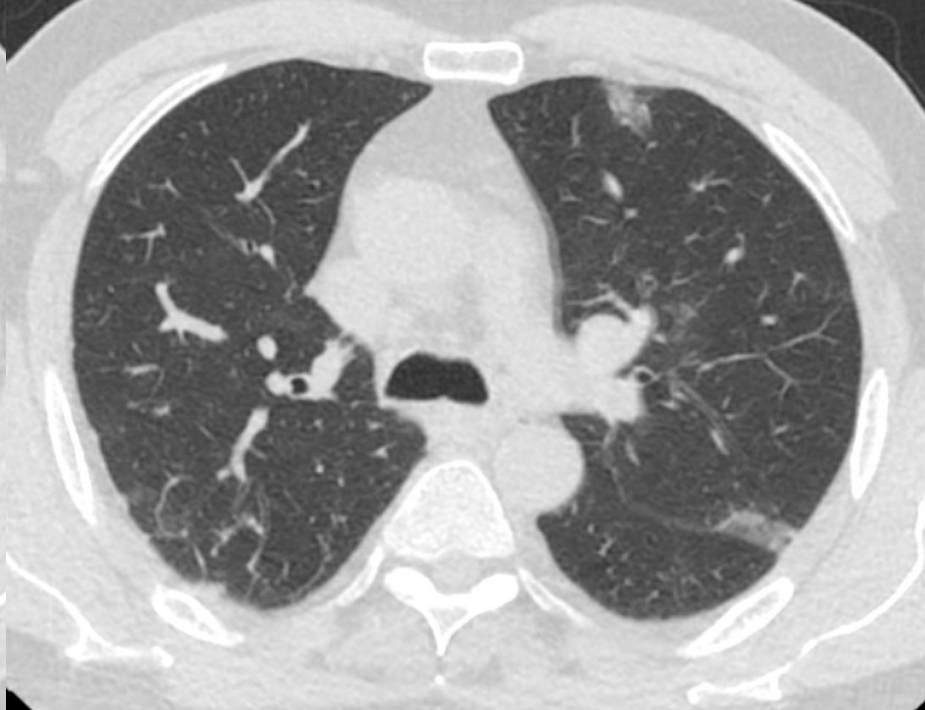
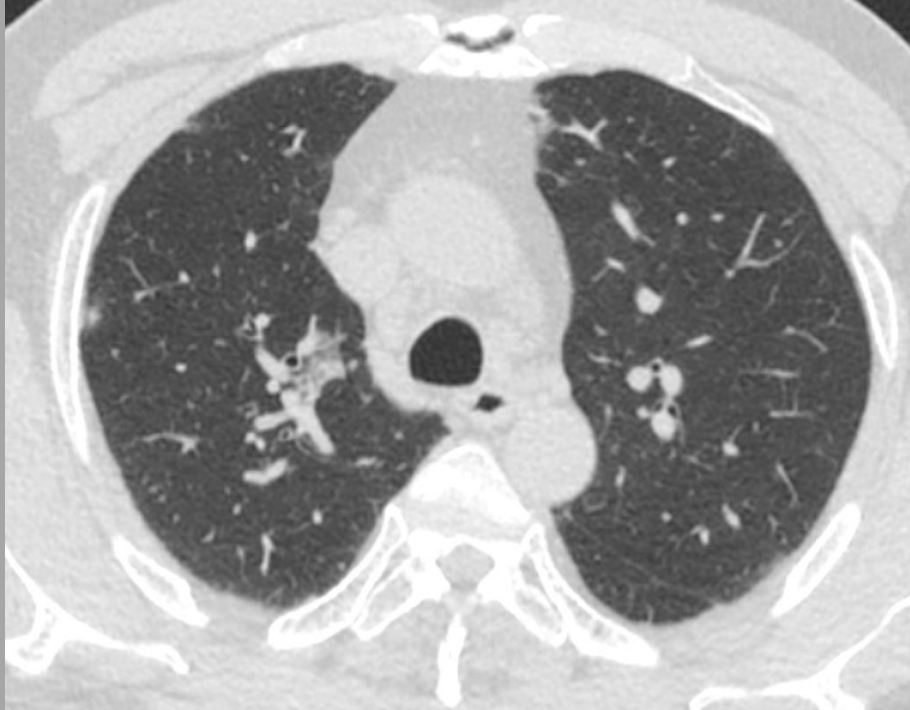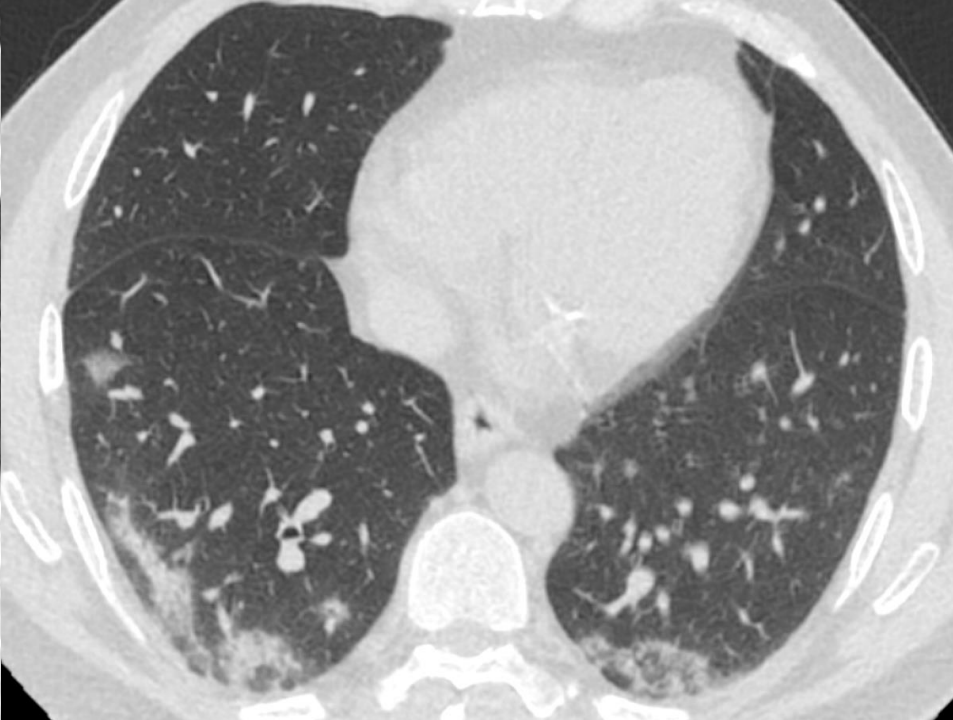
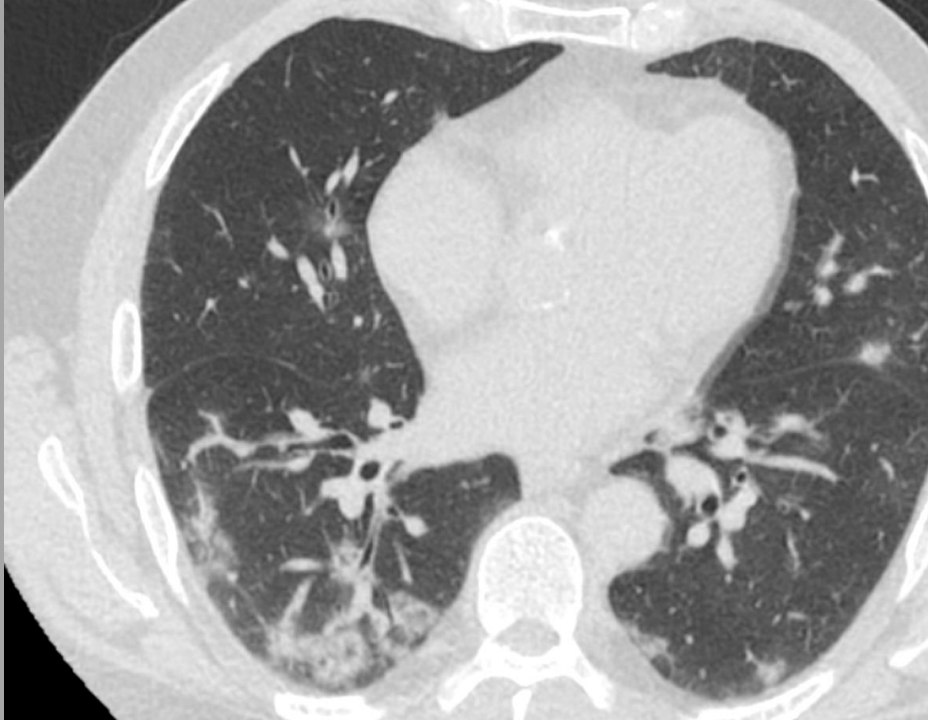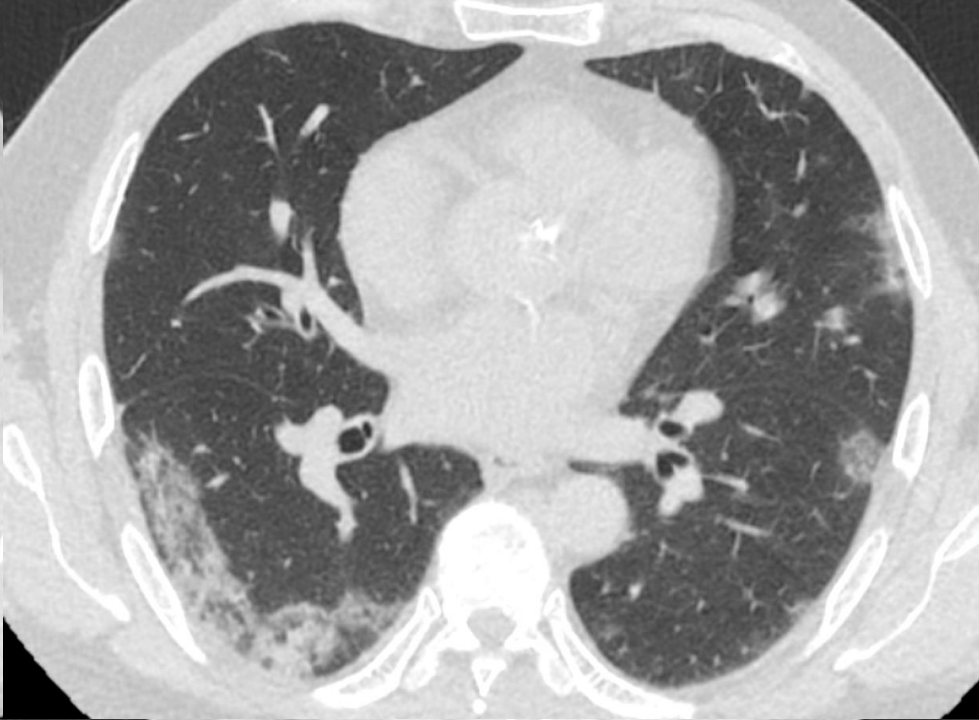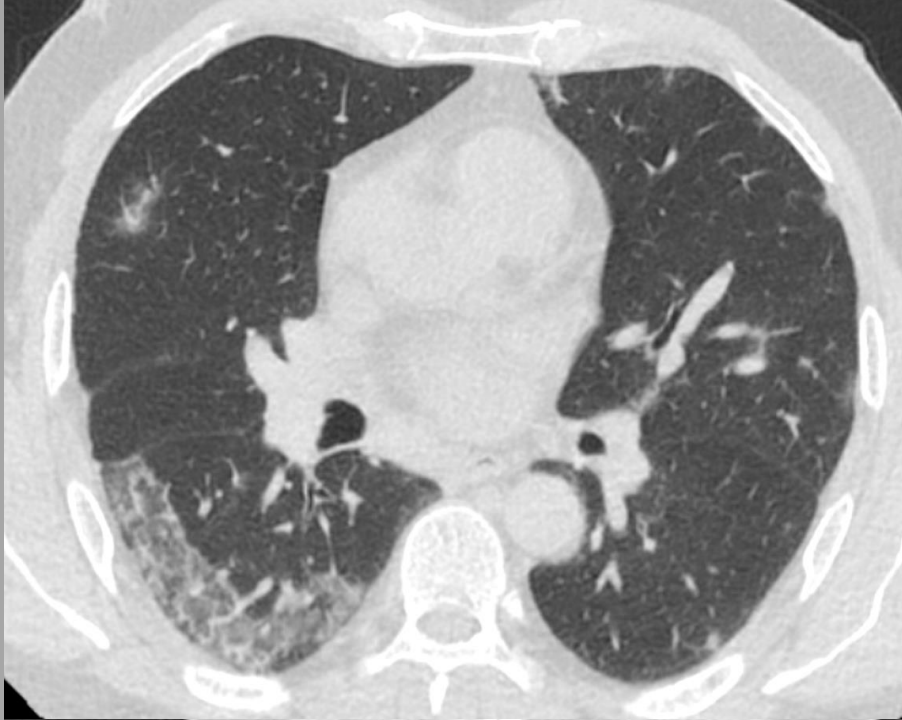
KASUISTIKA č. 3 - COVID-19

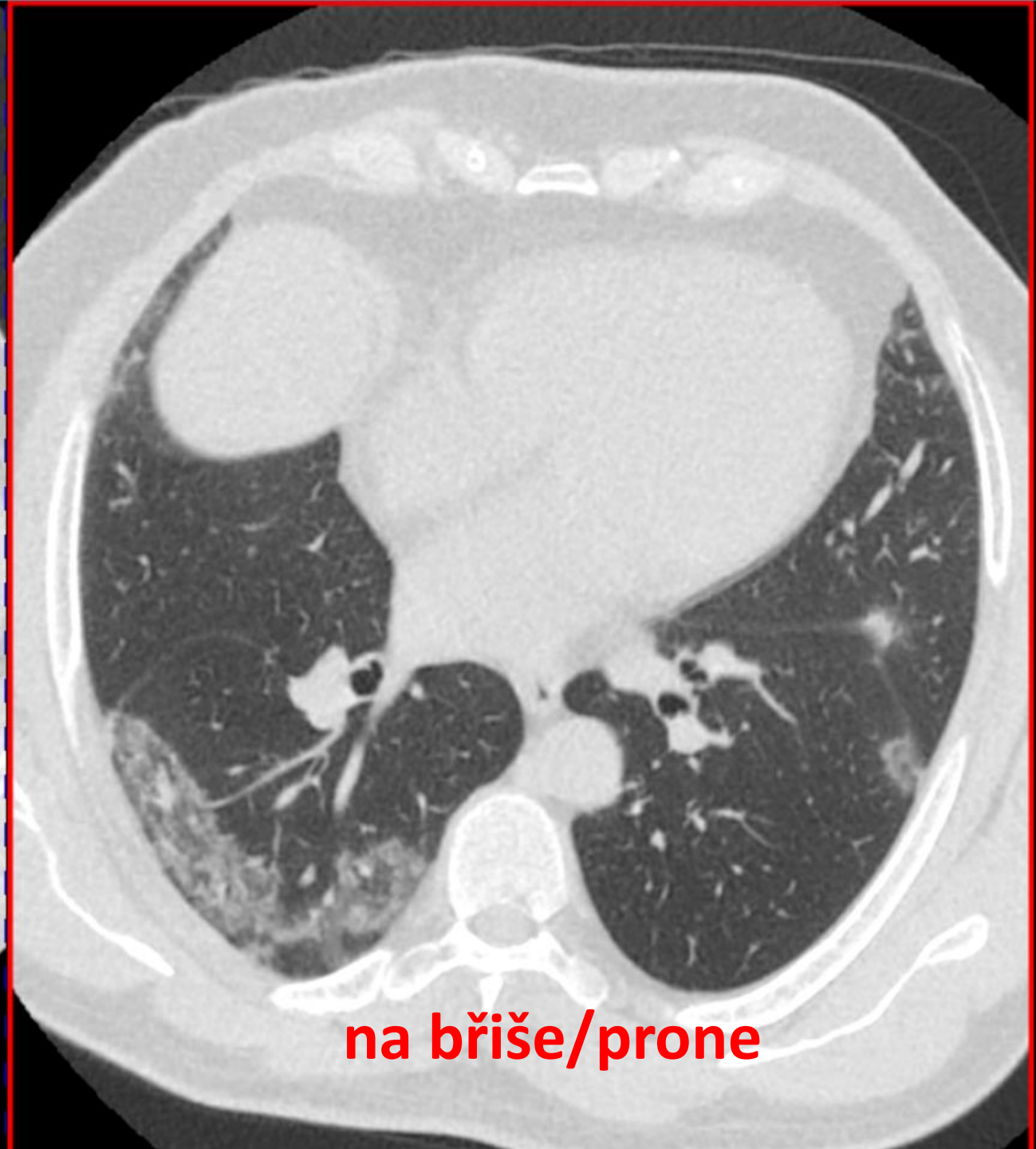
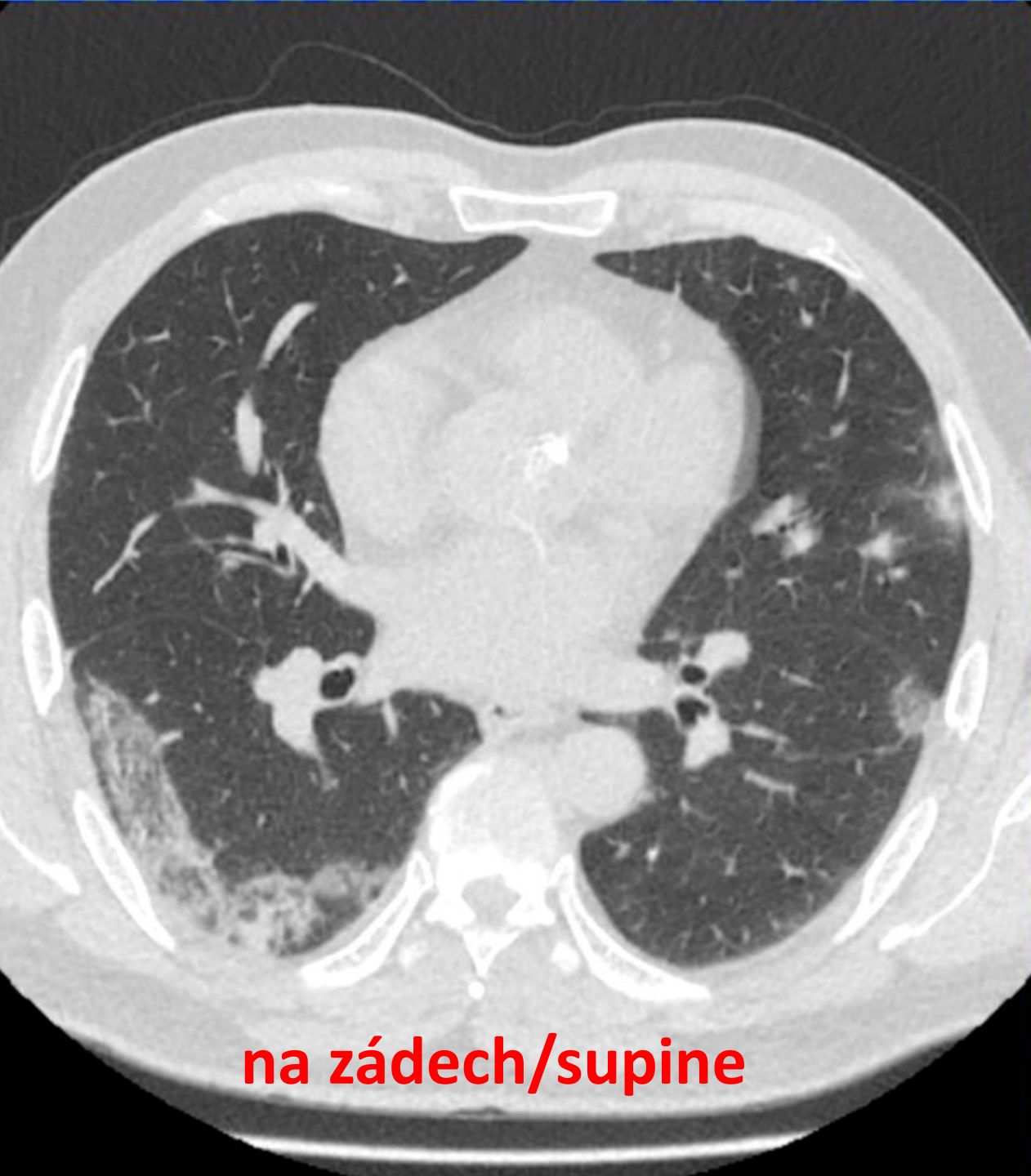CASE No. 3 - COVID-19

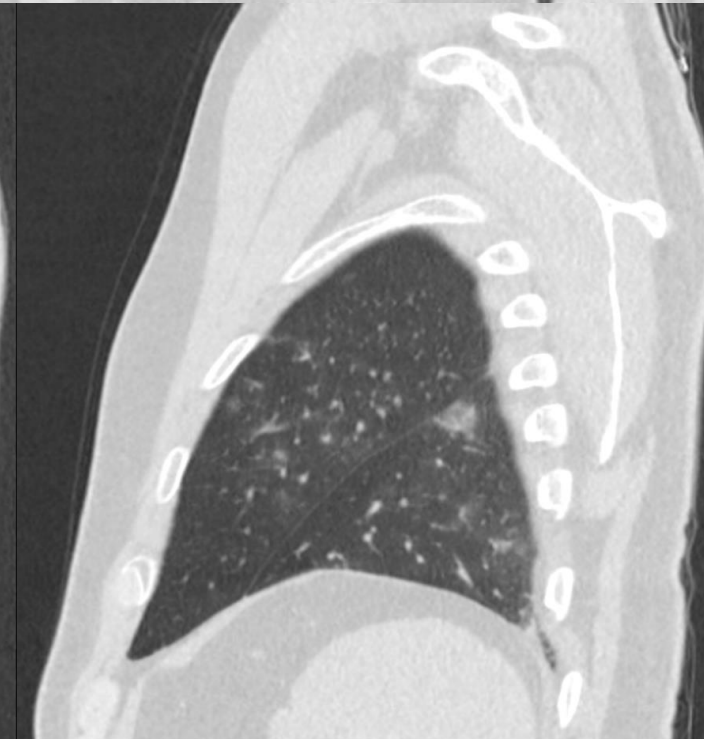
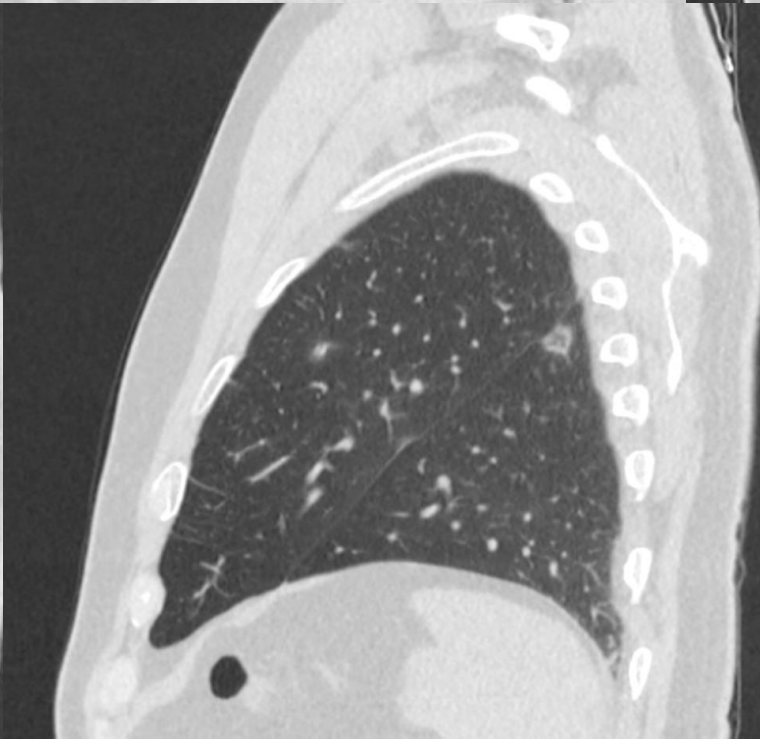
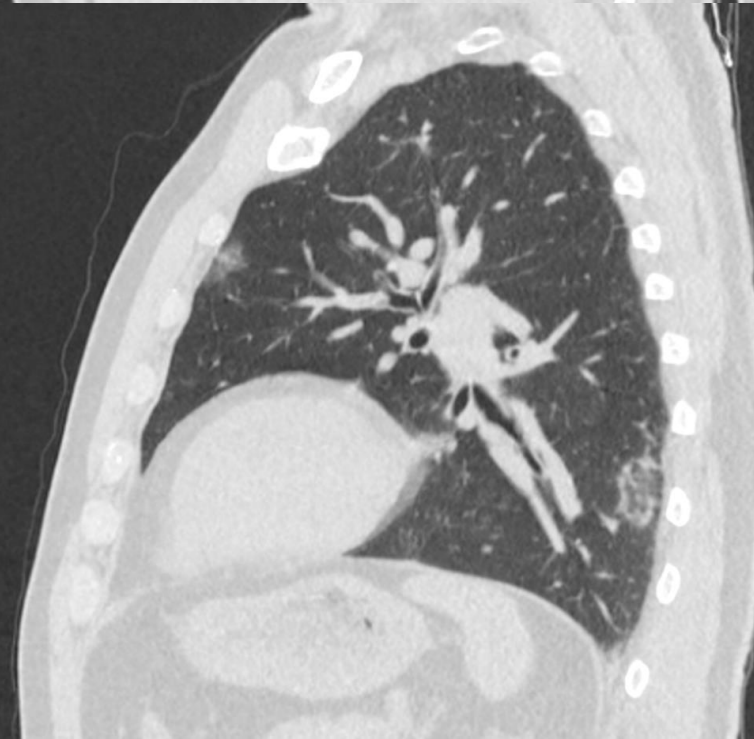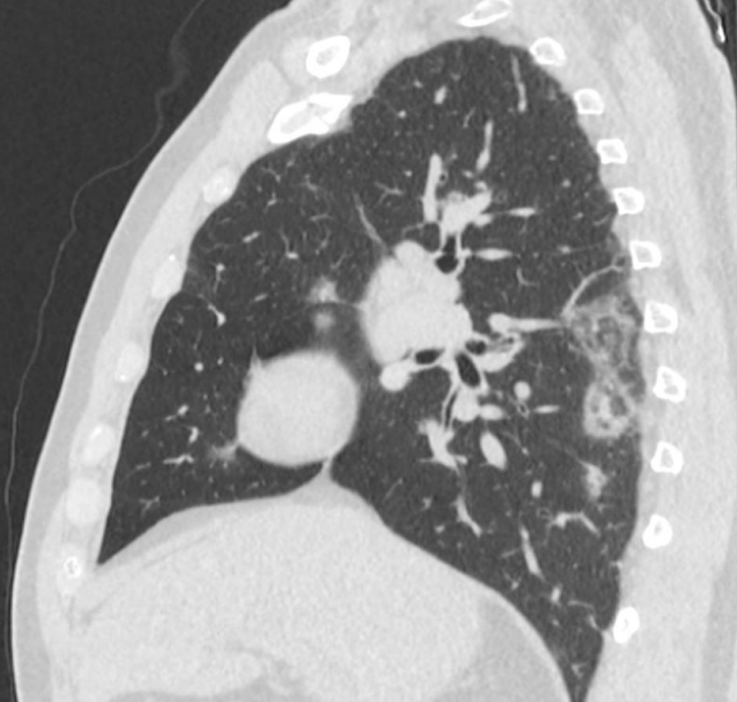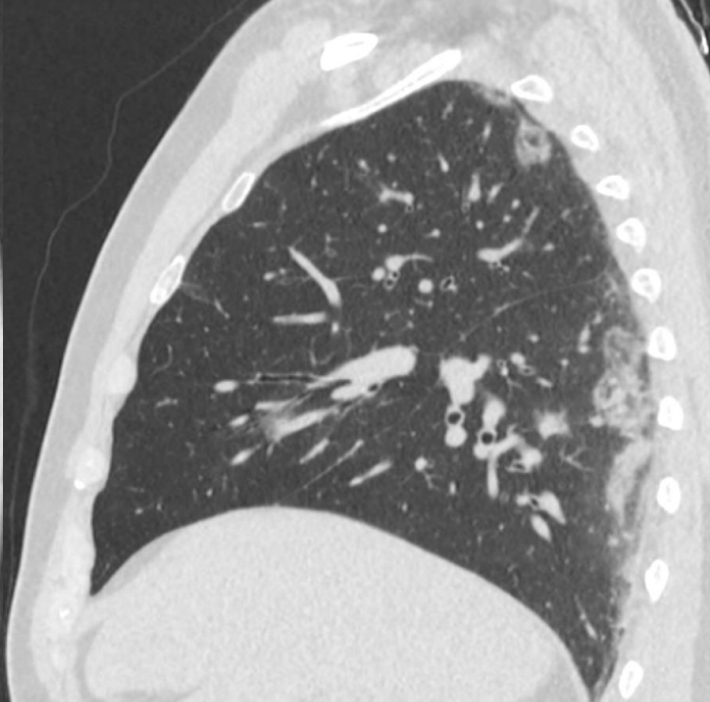
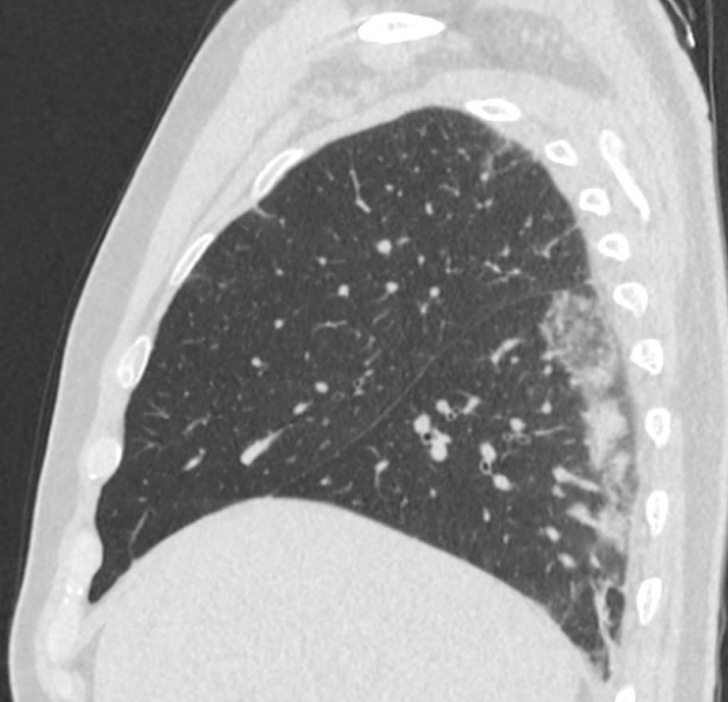
60letý muž, hypertonik se 13.3.2020 vrátil z Rakouska (Zaal Solden) s rodinou, po návratu jsou v domácí karanténě, od 15.3. začátek potíží - kolísavá teplota 37,5 - 38,5 st.C, postupná progrese suchého dráždivého kašle a dušnosti. V noci dechová tíseň s bolestí na hrudi, kvůli které nemohl spát, RT-PCR SARS-CoV-2 pozitivní

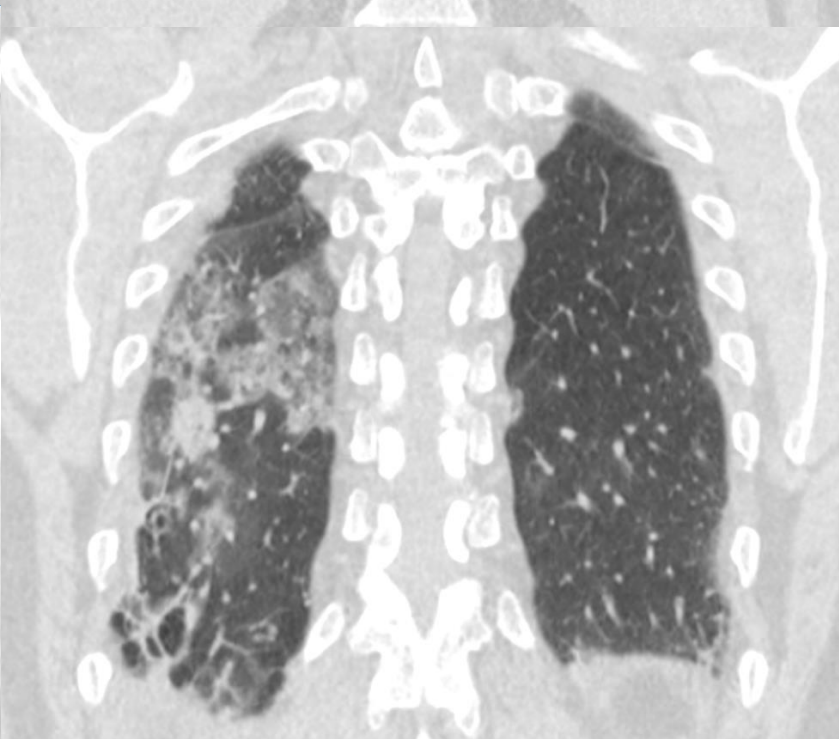
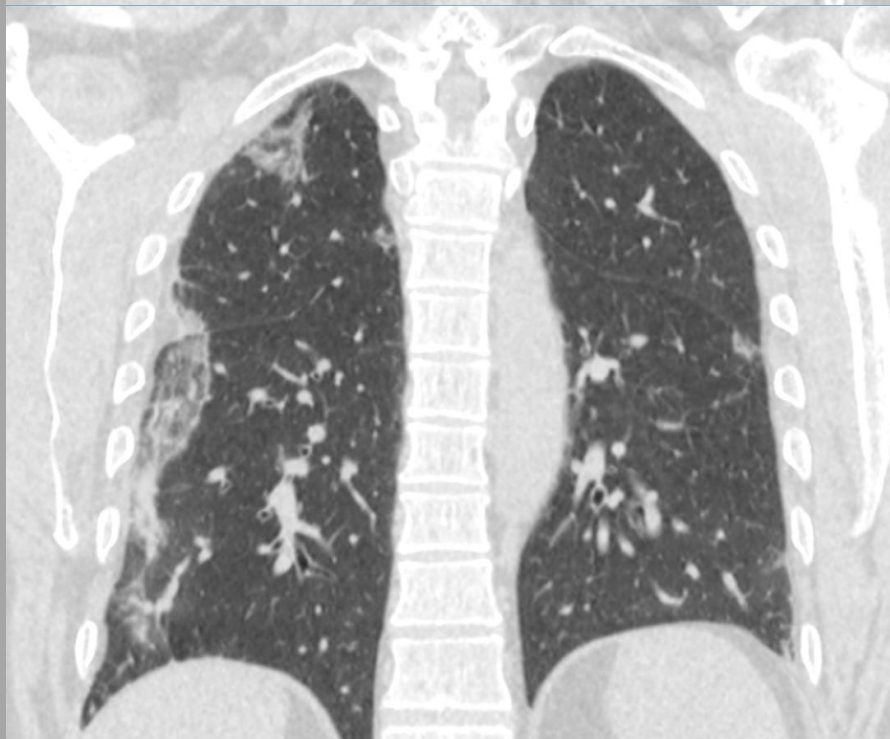
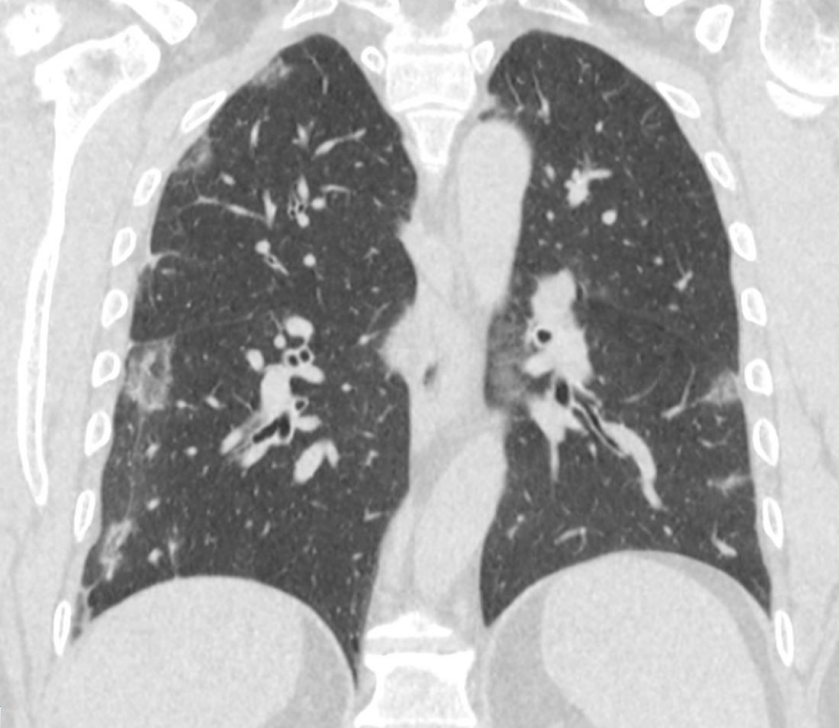
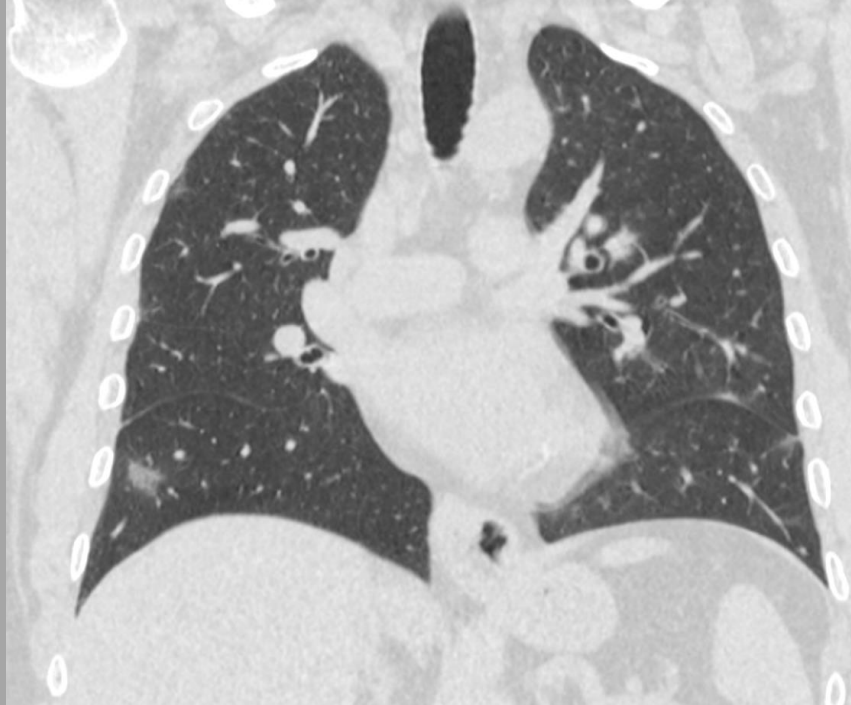male 60 yo, 13-3-2020 returned from skiing in Austria in quarantine, 15-3-2020 onset of the symptoms, alternating fever 37.5 to 38.5 Celsius gr., progression of the dry cough and dyspnea, breathing anxiety and chest pain at night, cannot asleep, RT-PCR SARS-CoV-2 positive









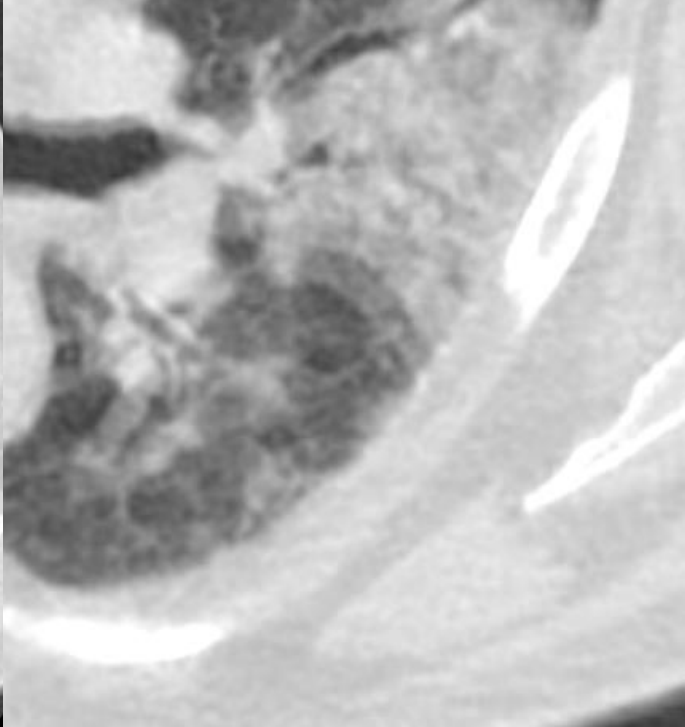
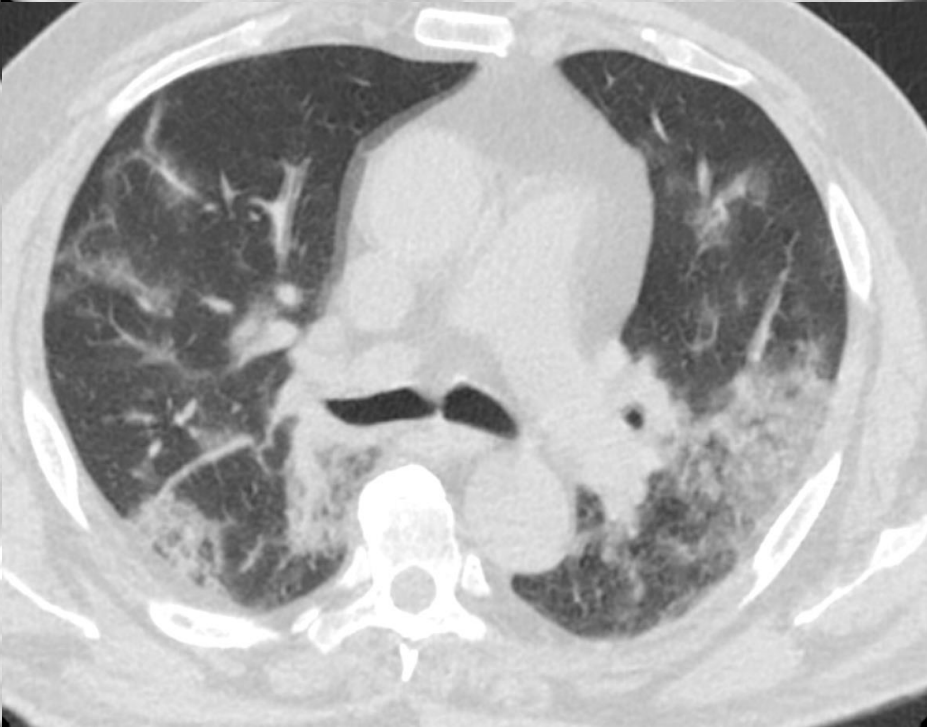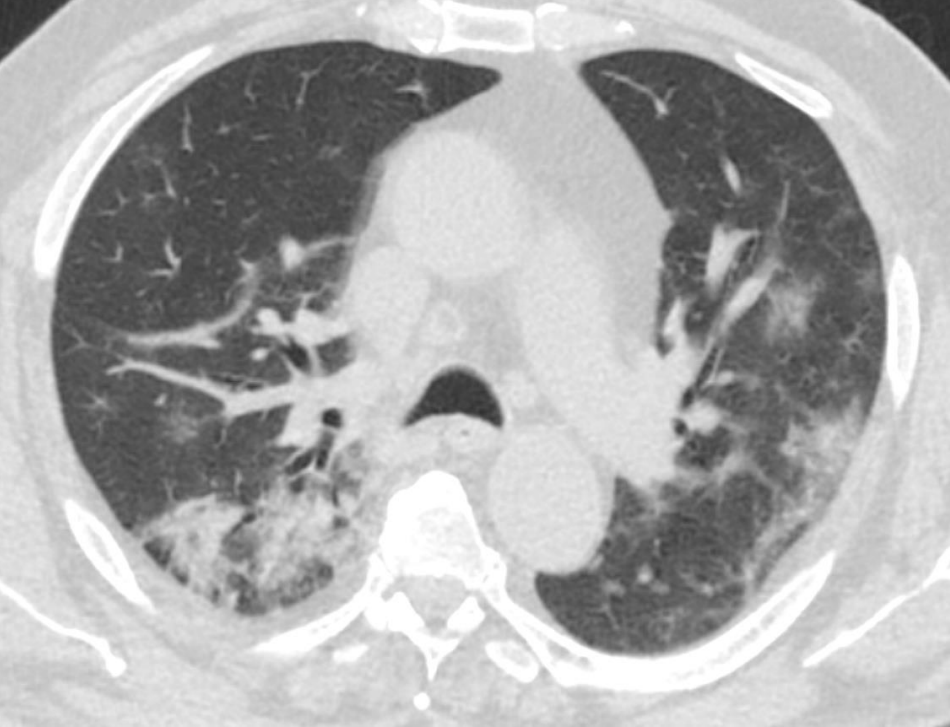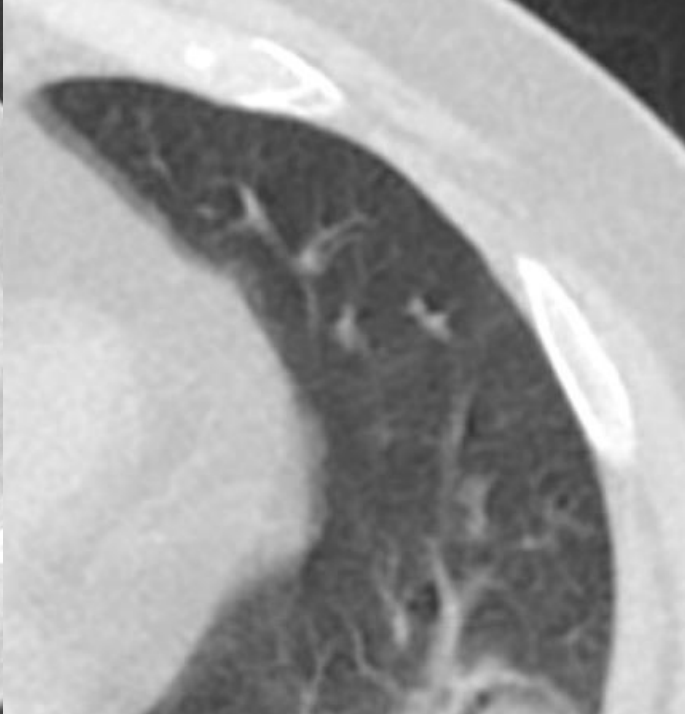


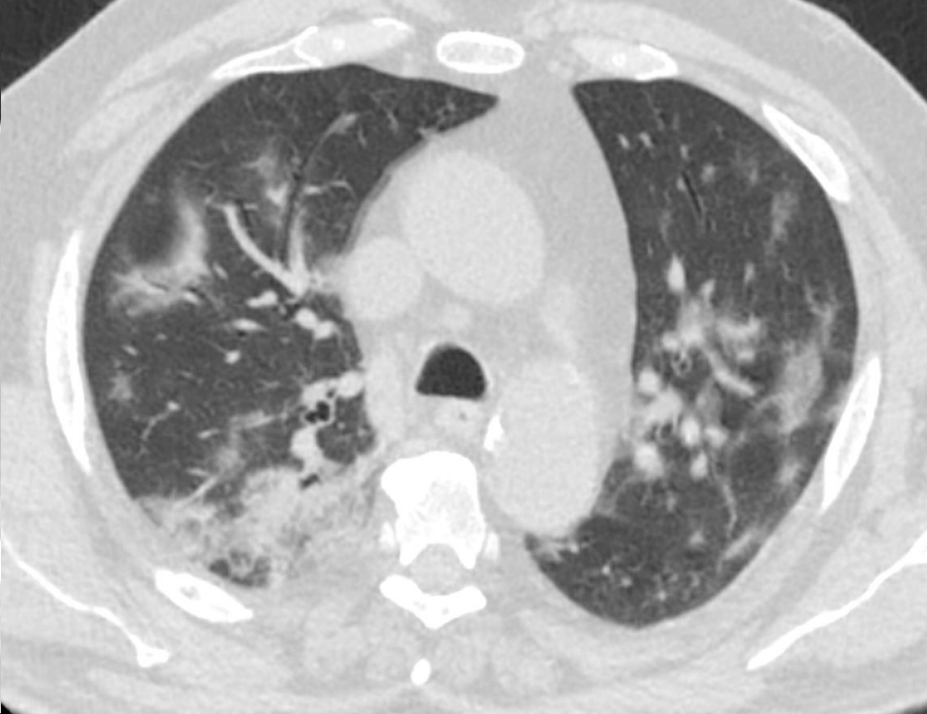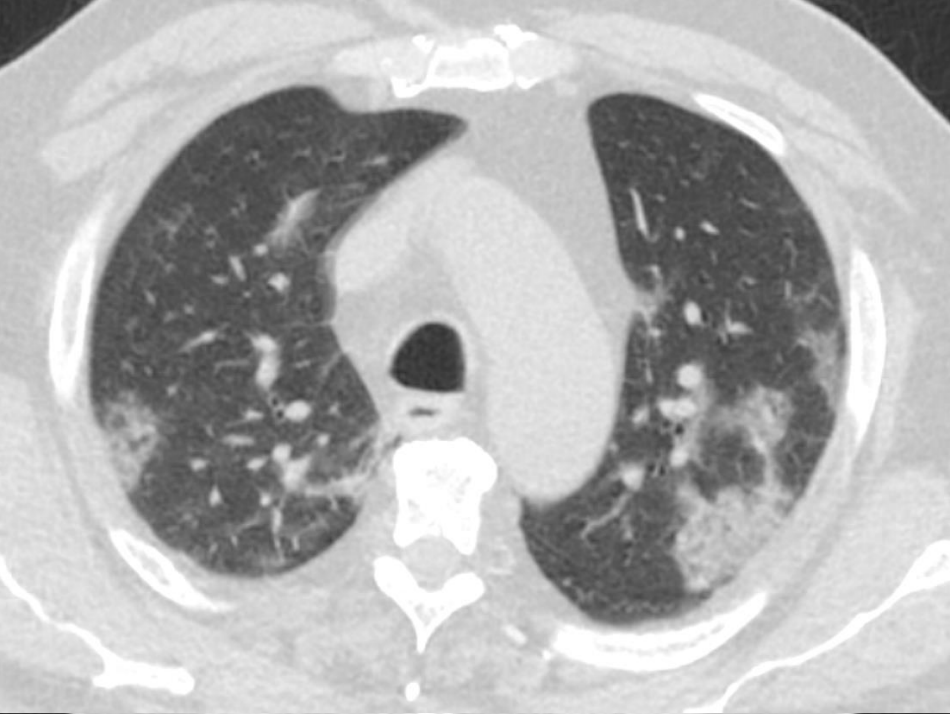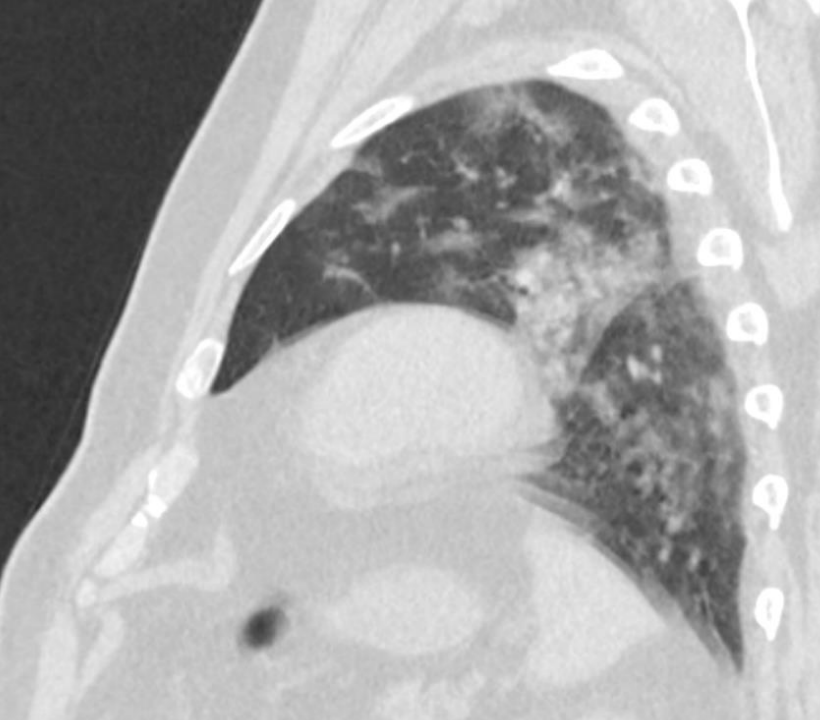
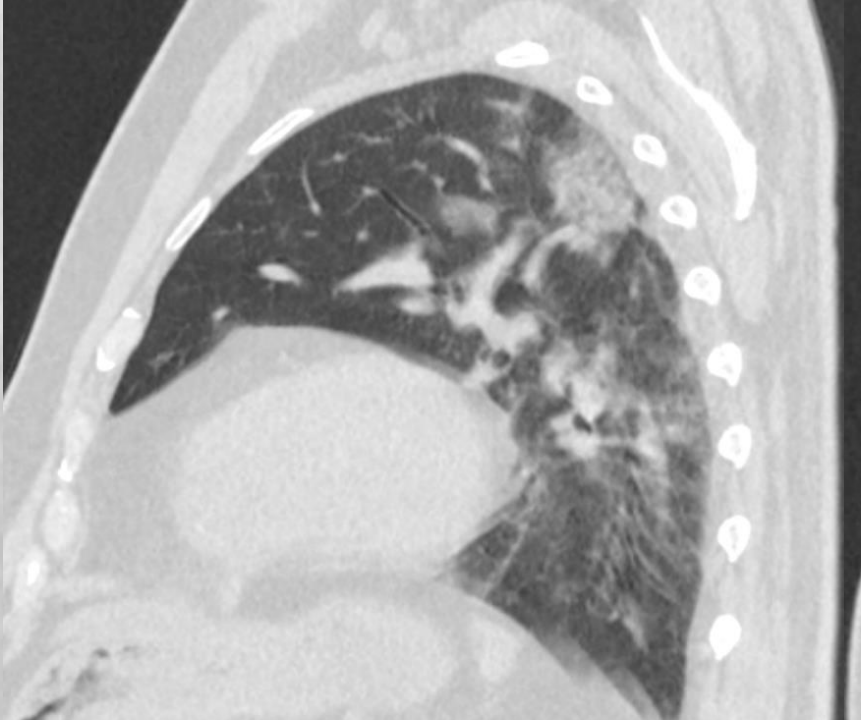
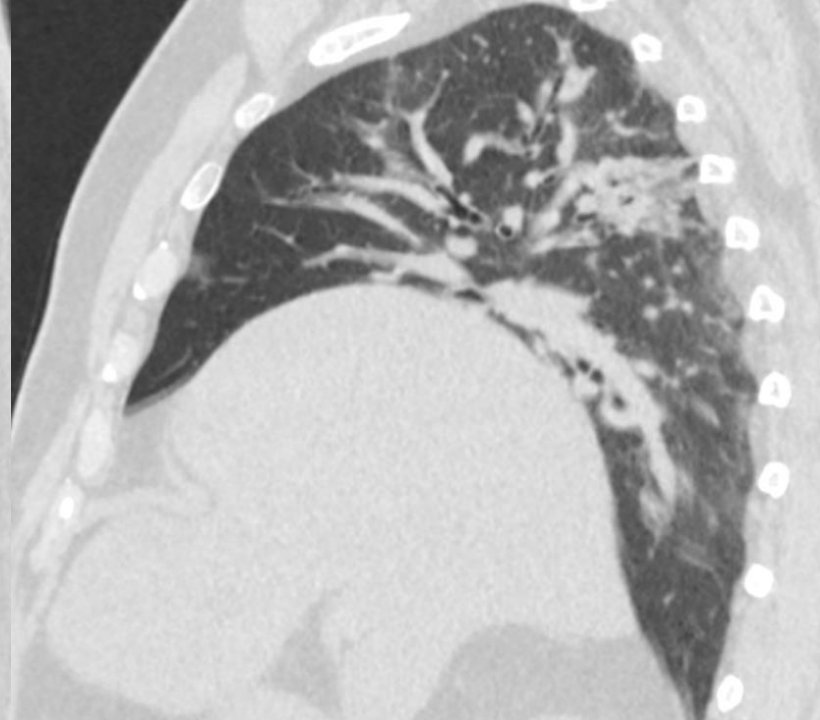
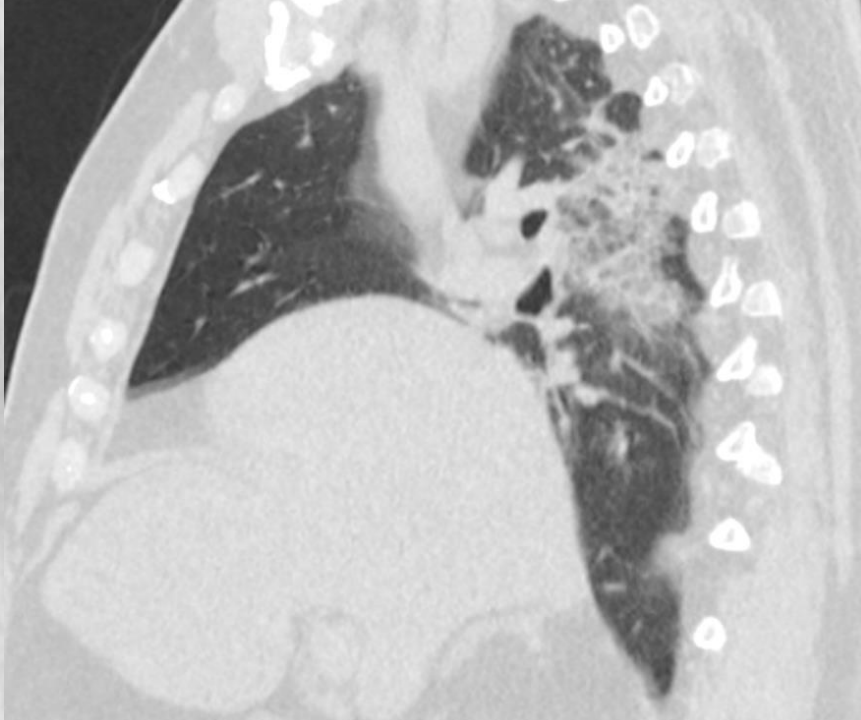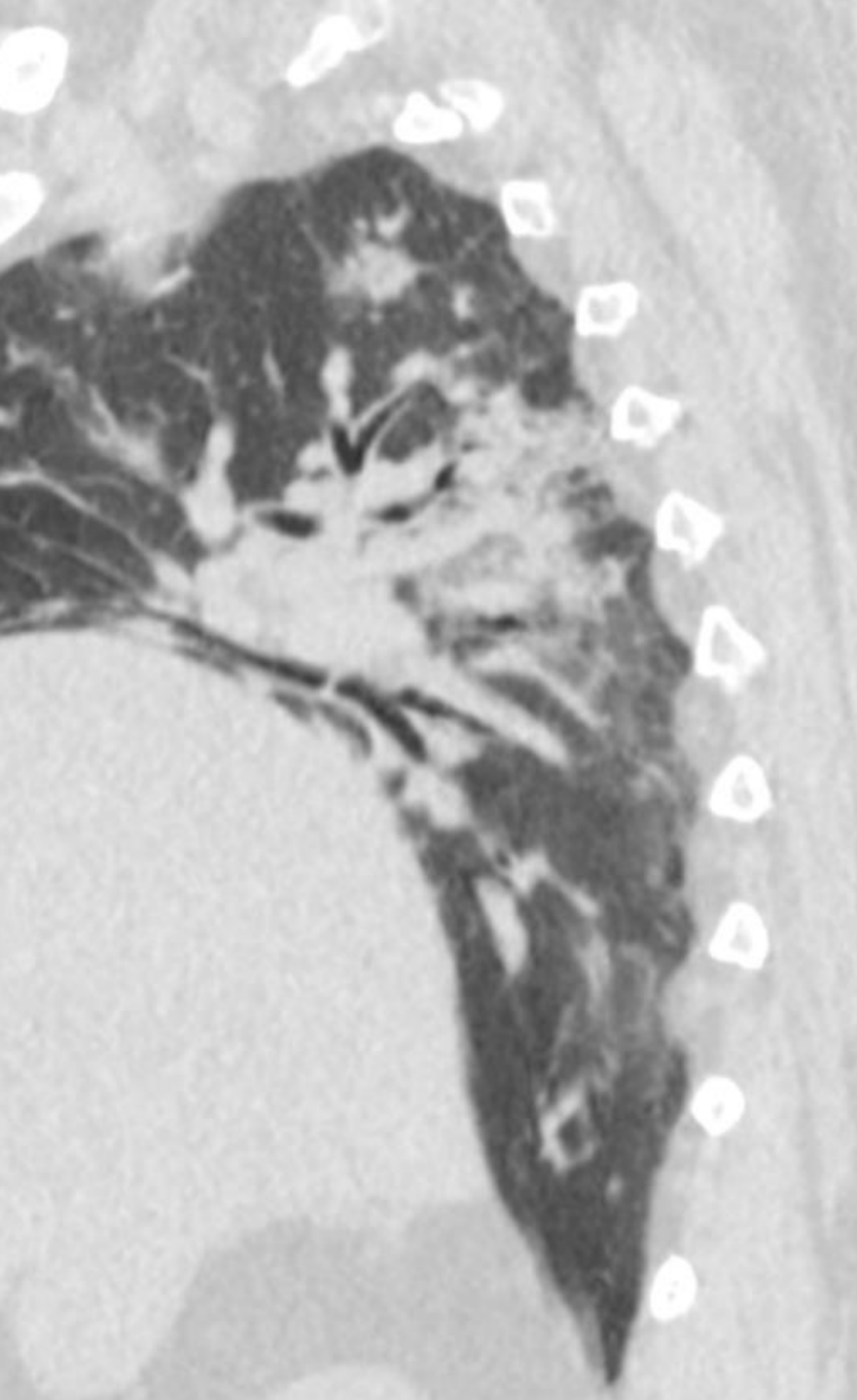
KASUISTIKA č. 4 - COVID-19

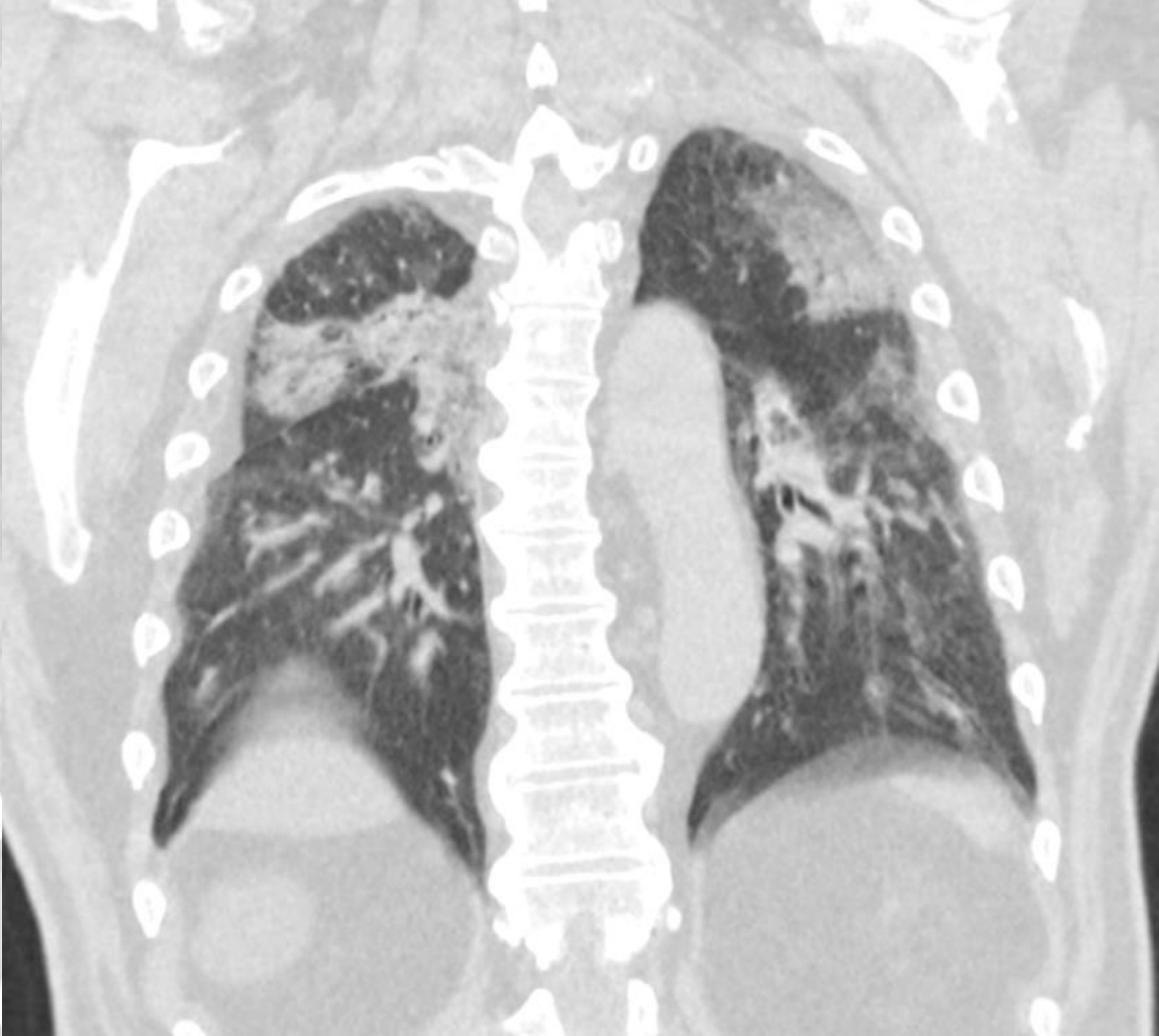
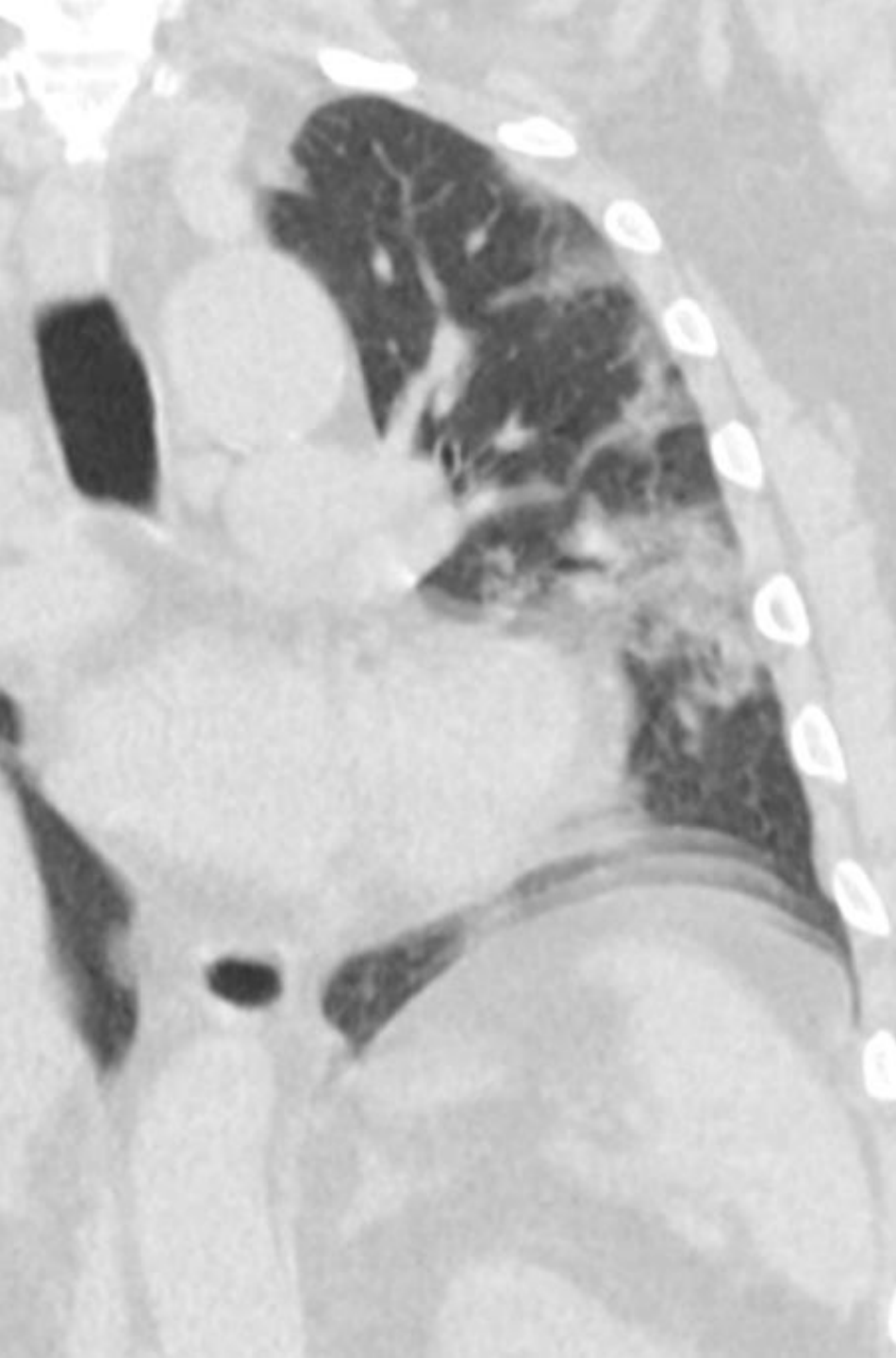
CASE No. 4 - COVID-19

69-letý muž, horečka 39 st. Celsia, 4 dny suchý dráždivý kašel, přivezen pro zhoršení dechu, dechová tíseň, malátný, přivezen RZP, stýká se se synem, pracujícím v Německu, podezření na COVID-19, později RT-PCR SARS-CoV-2 pozitivní

male 69 yo, fever 39 Celsius gr., four days dry irritative cough, progression of the dyspnea, breathing anxiety , fatigue, son is working in Germany, suspected COVID19, later RT-PCR SARS-CoV-2 positive





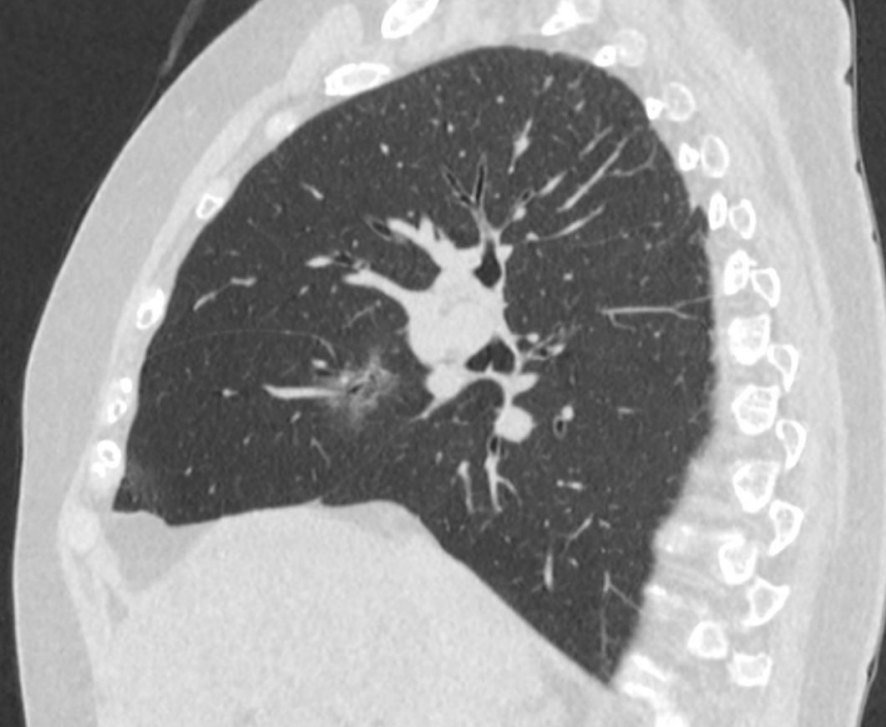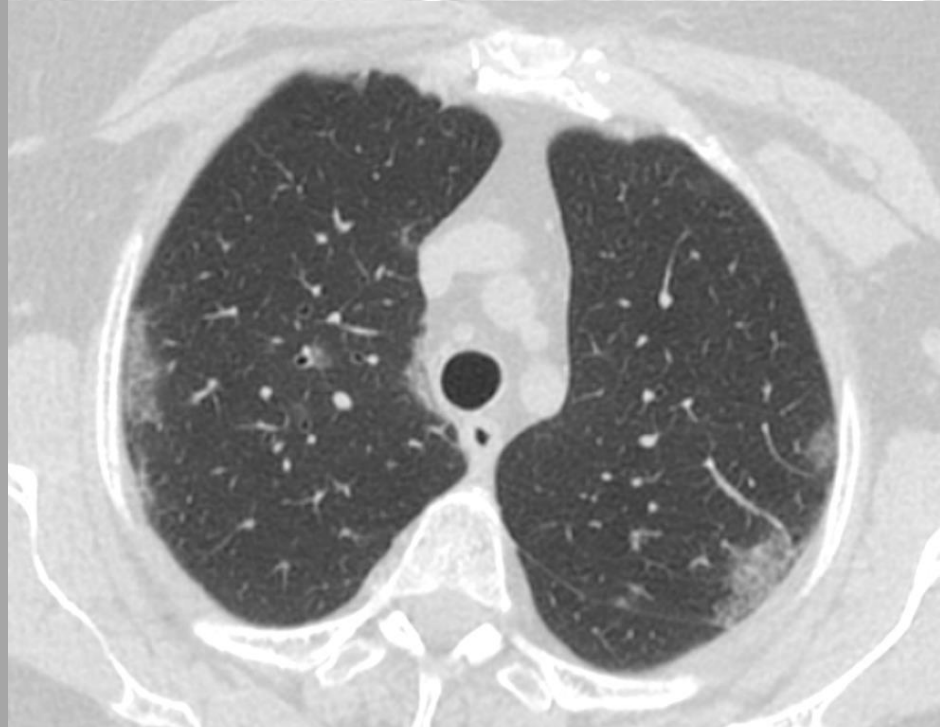

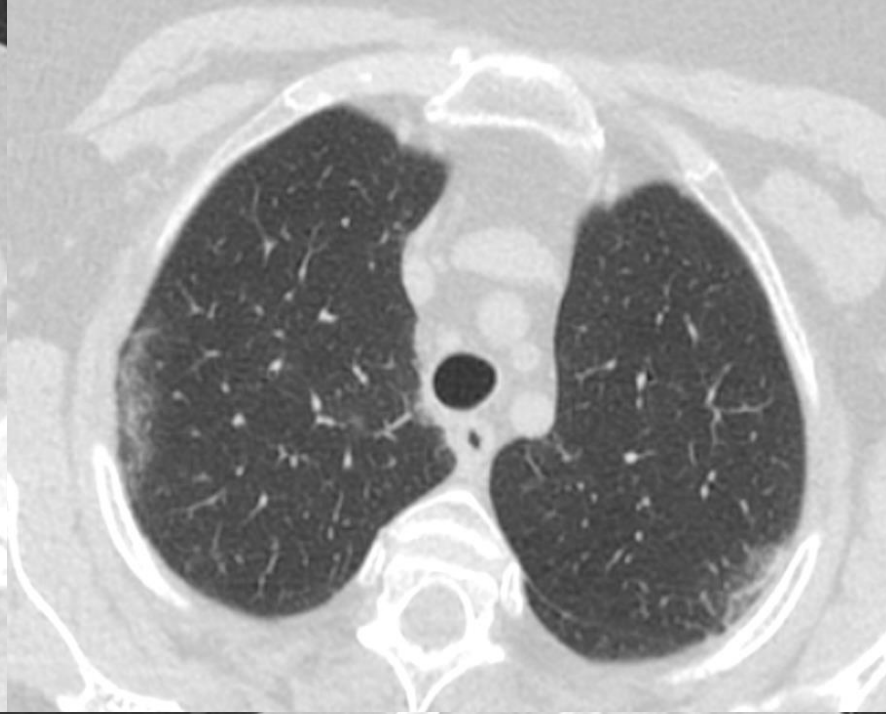
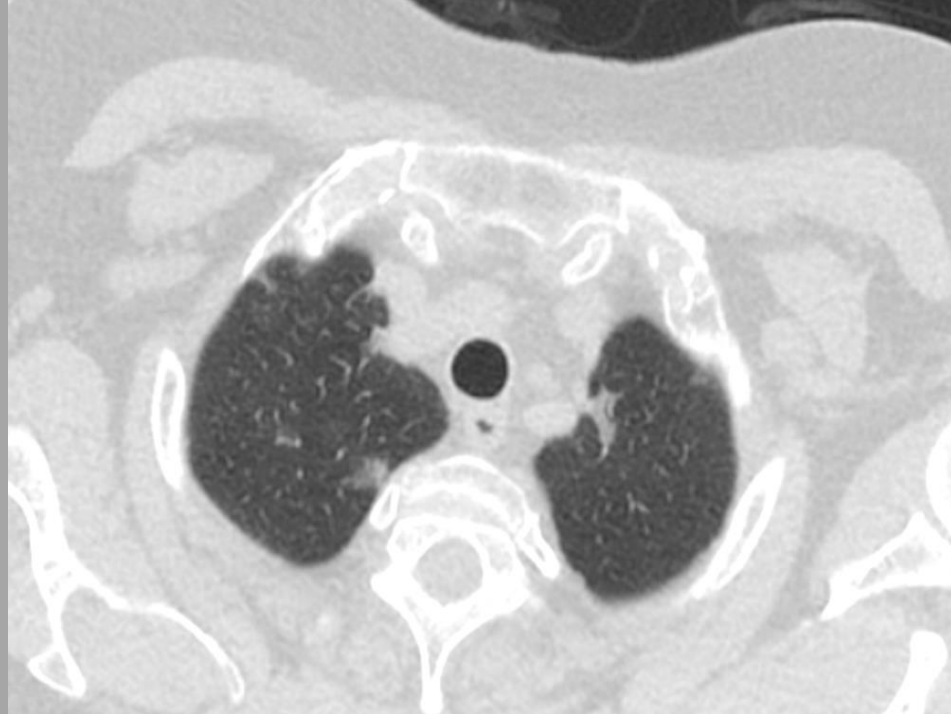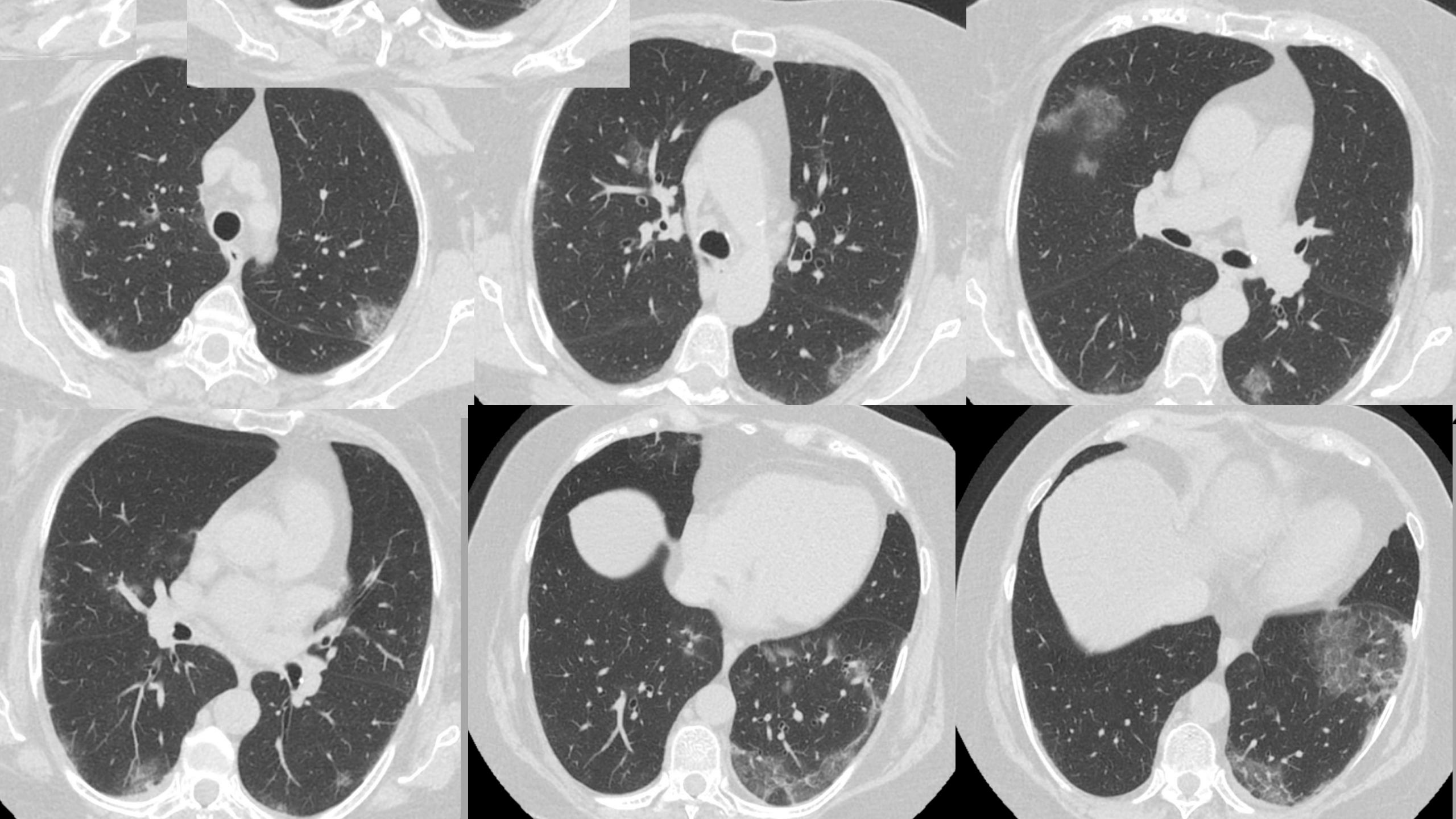
KASUISTIKA č. 5 - COVID-19

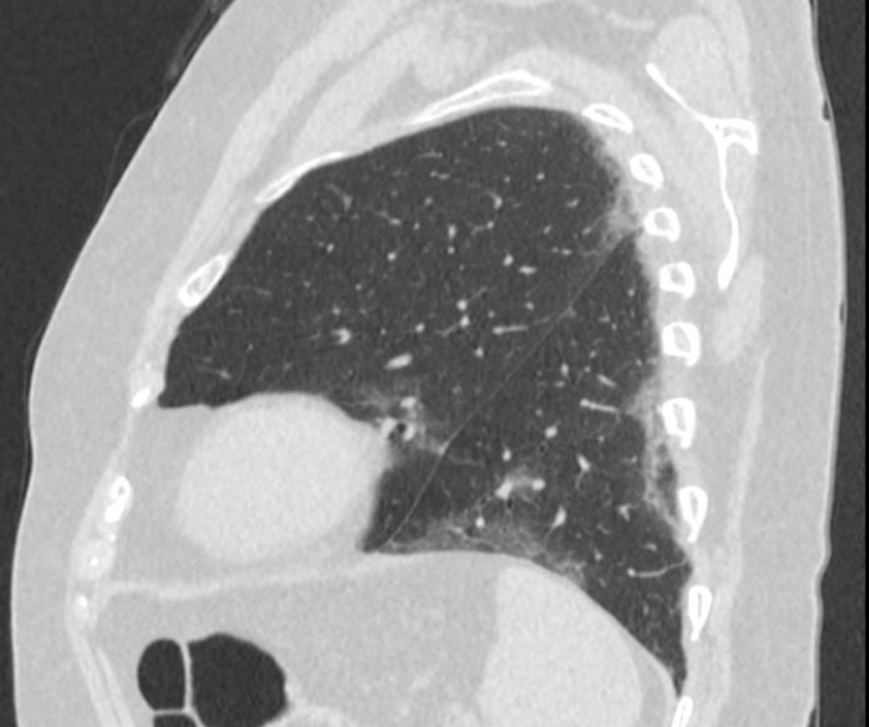
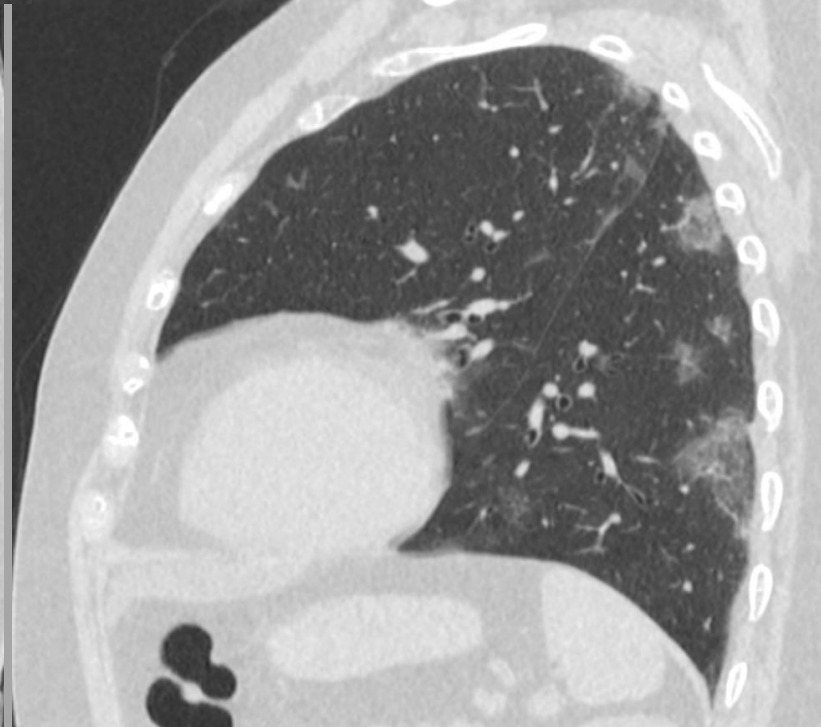
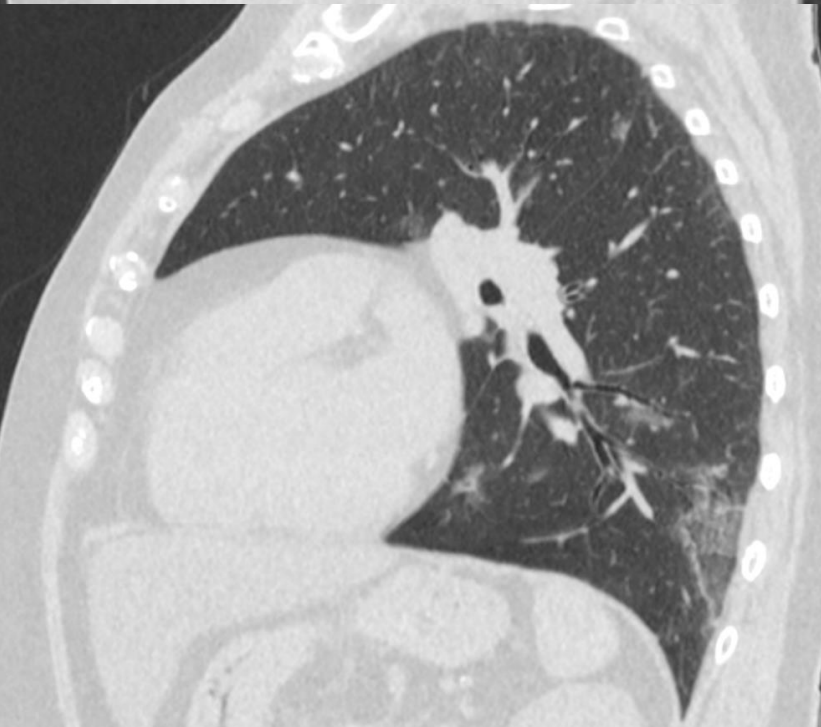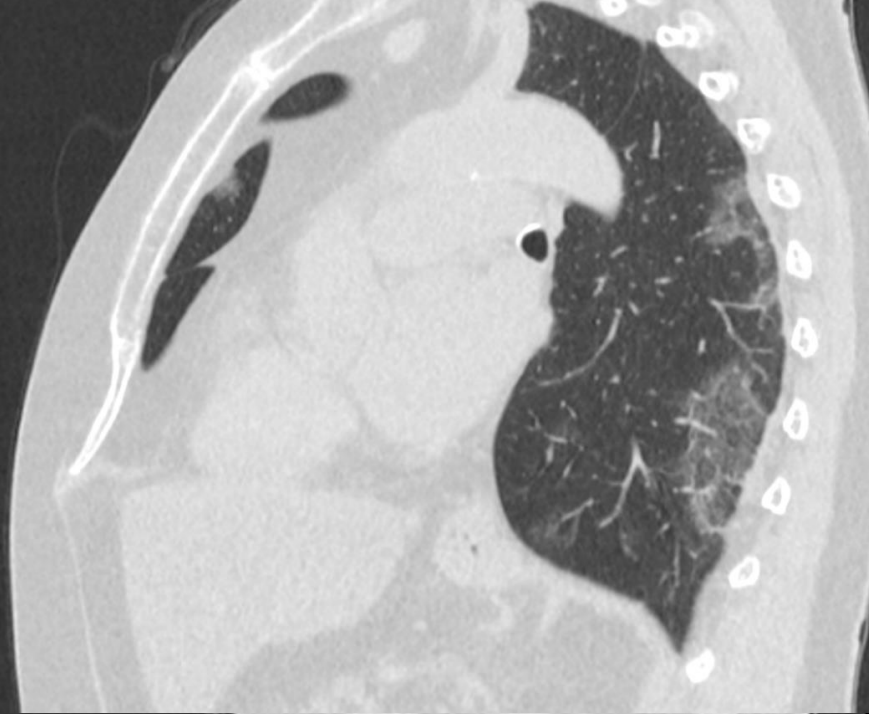
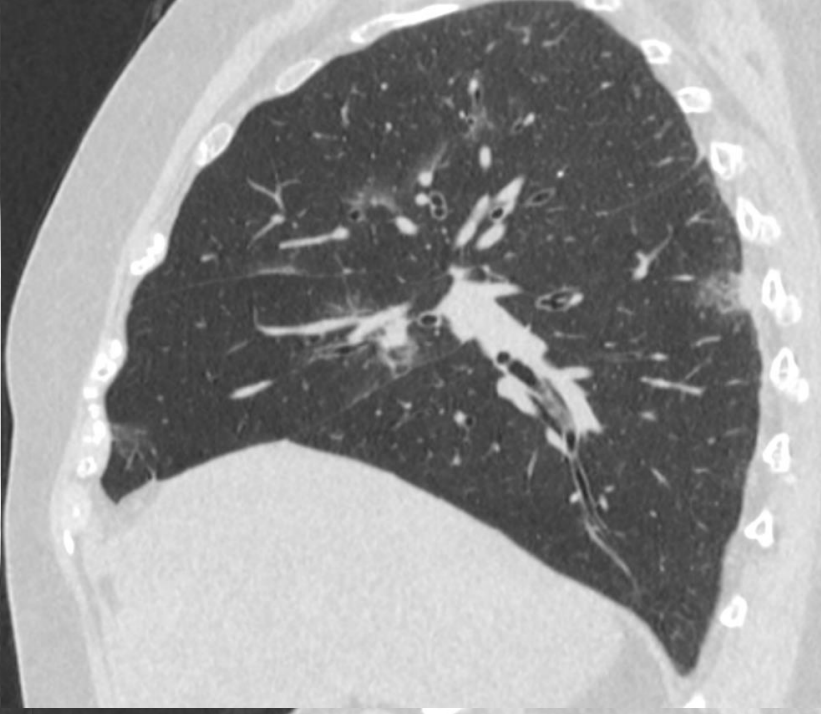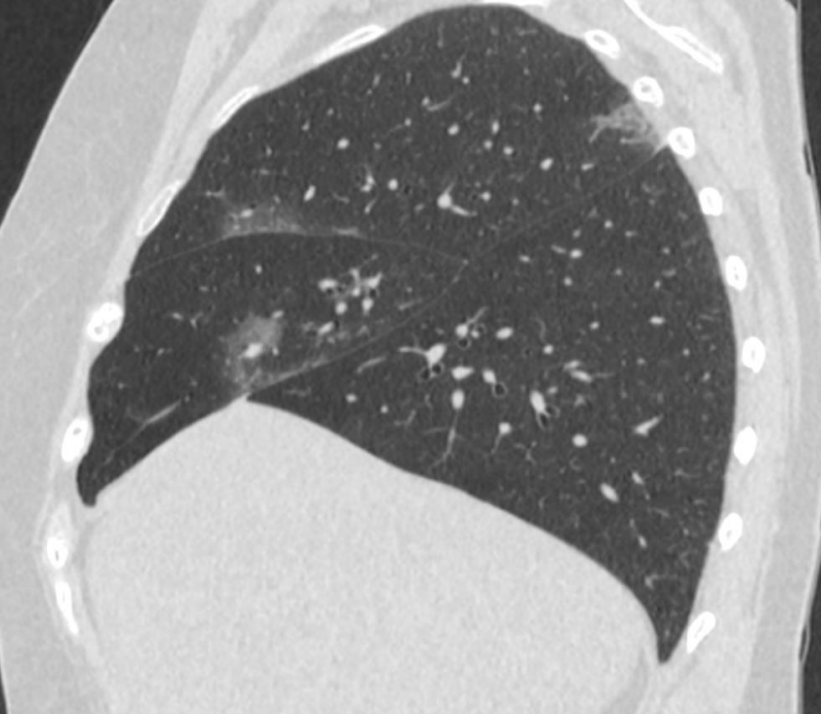
CASE No. 6 - COVID-19

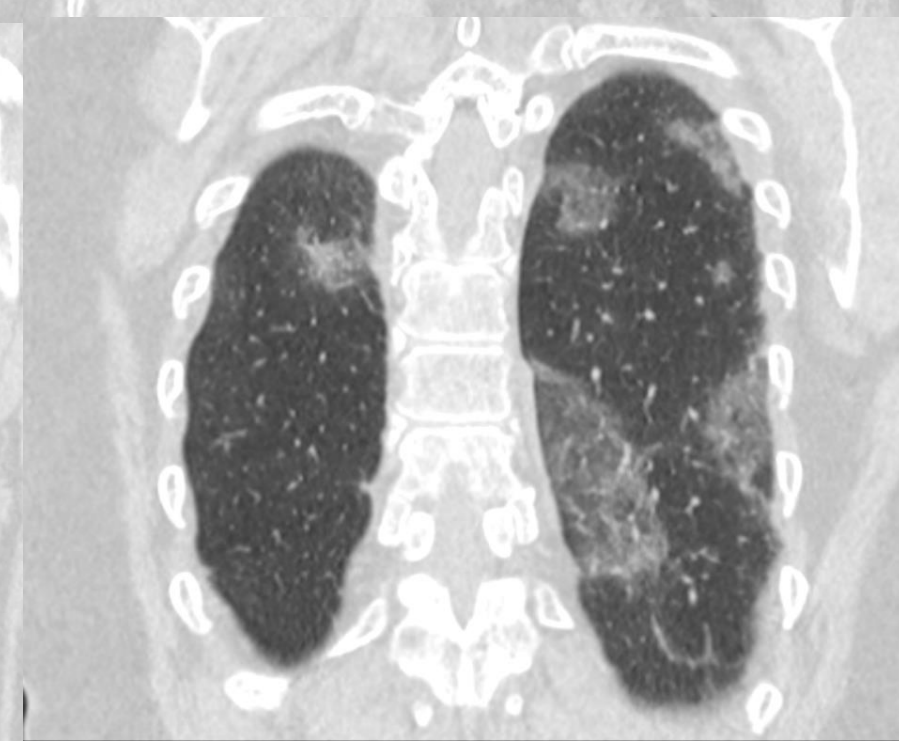
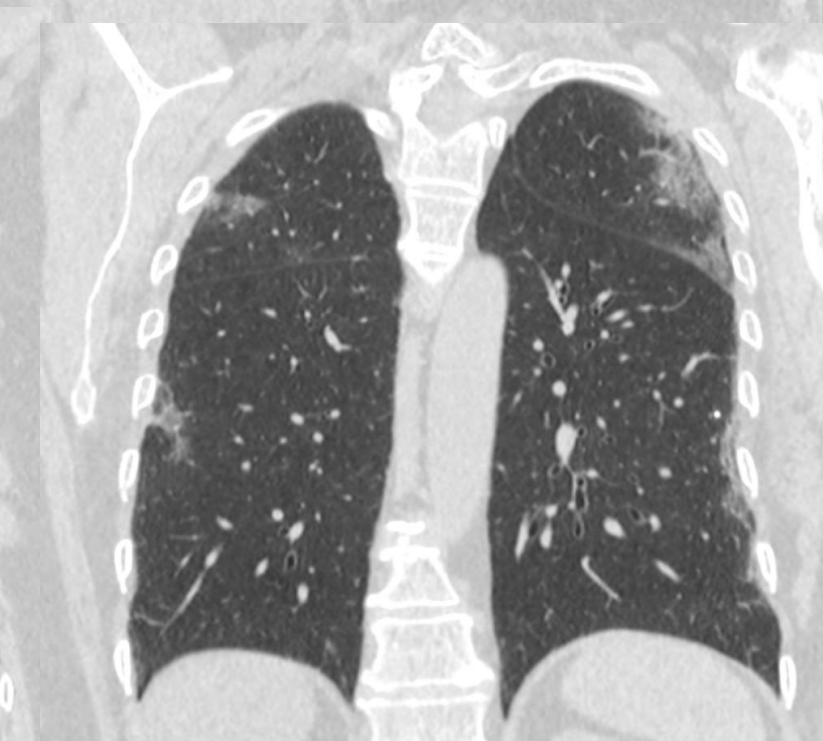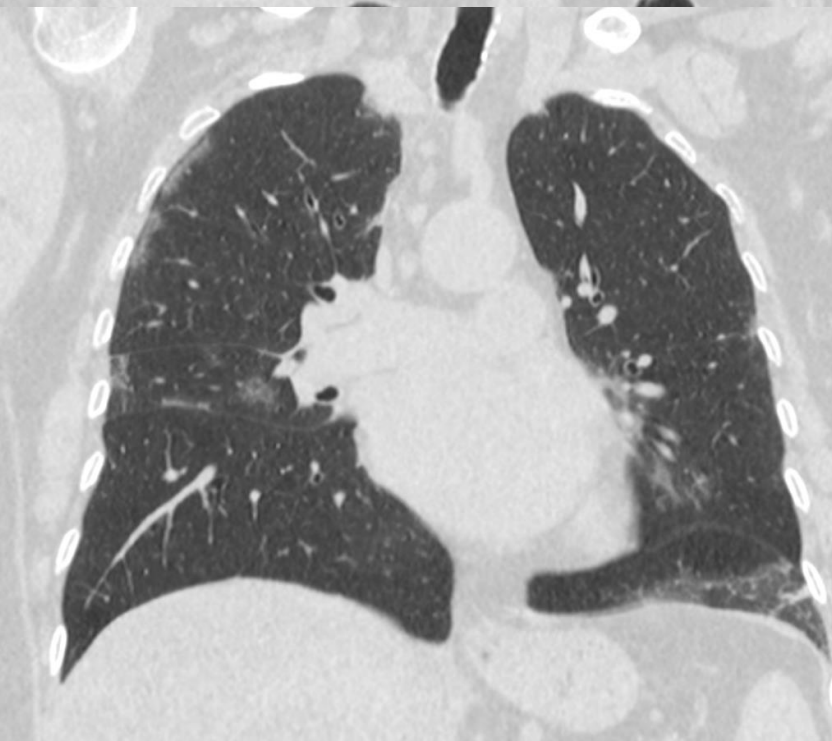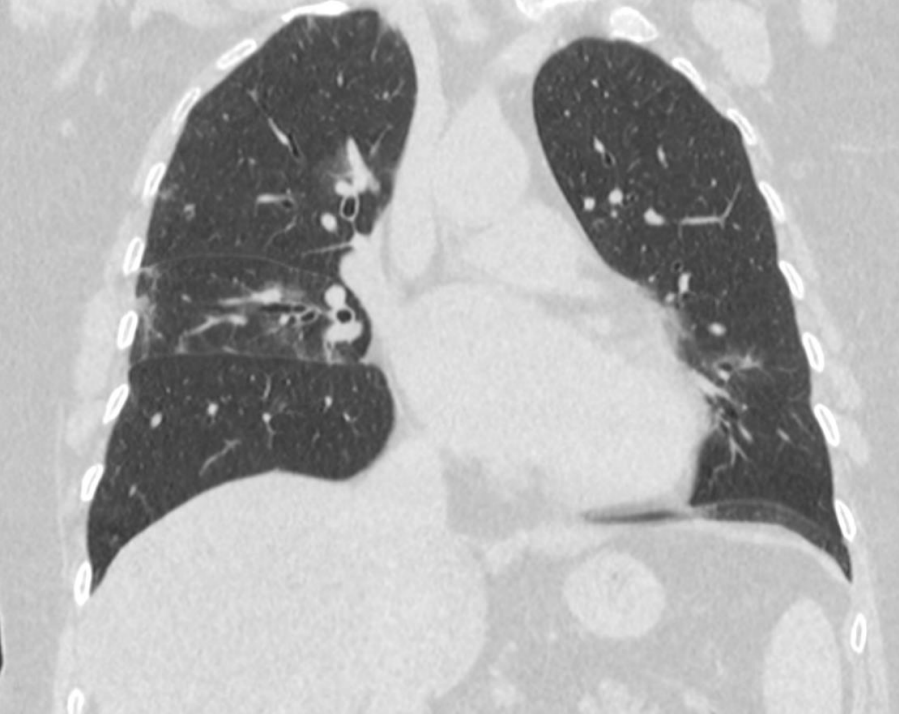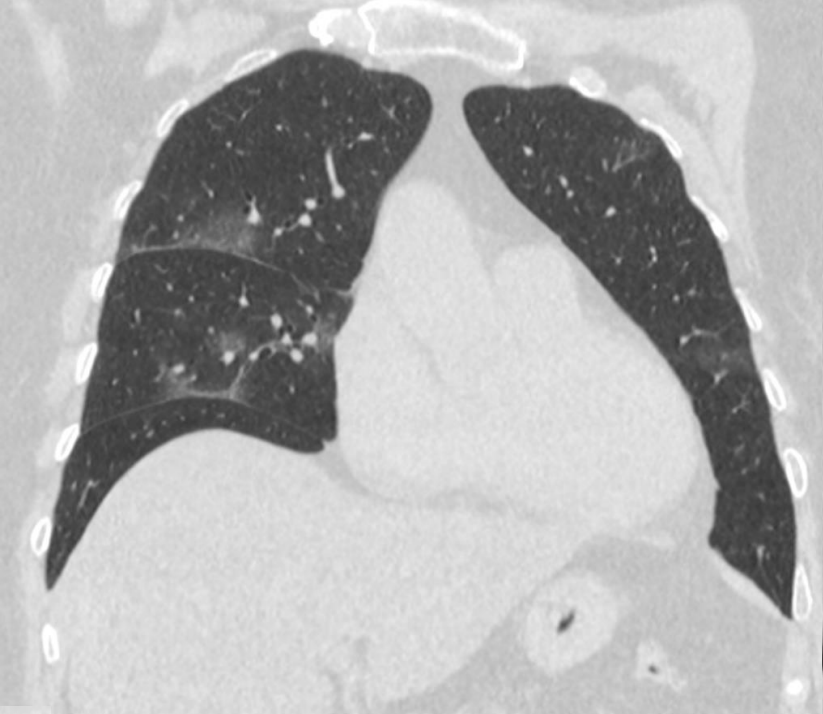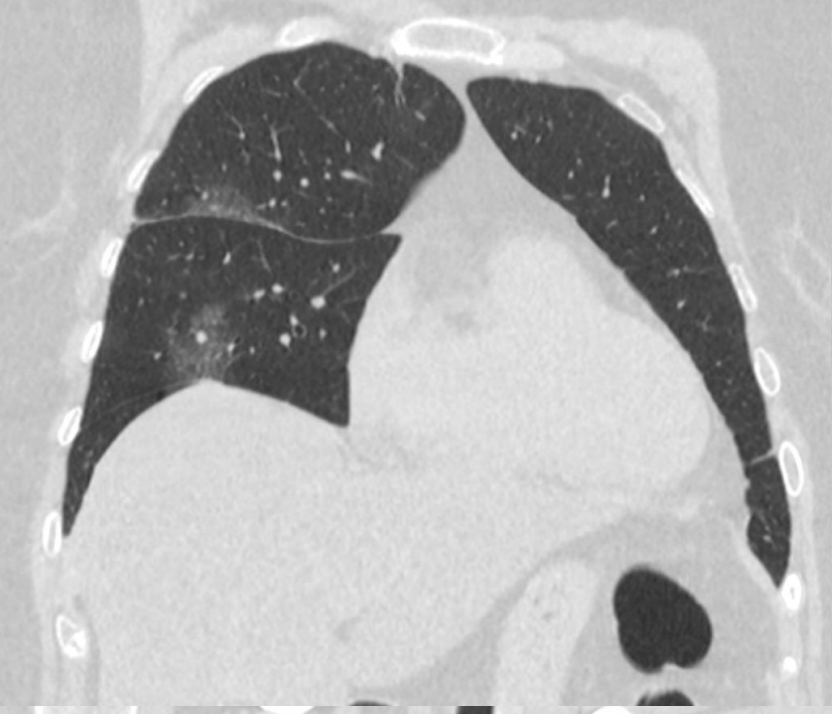
71-letá žena, teploty 37,5 st. Celsia, 7 dní zhoršený kašel, zvracení, manžel (kasuistika 5) potvrzen COVID-19, stýká se se synem, pracujícím v Německu, podezření na COVID-19, později RT-PCR SARS-CoV-2 pozitivní

female 71 yo, subfebrile 37.5 Celsius gr., seven days cough, vomitus, husband (case 5) confirmed as COVID-9, son is working in Germany, suspected COVID19, later RT-PCR SARS-CoV-2 positive







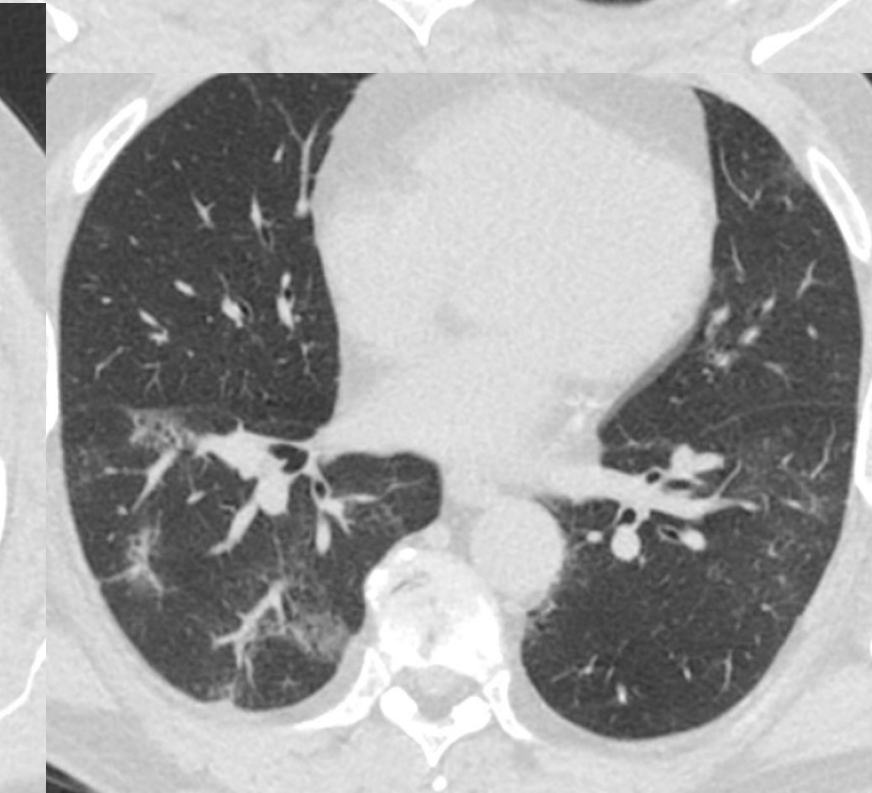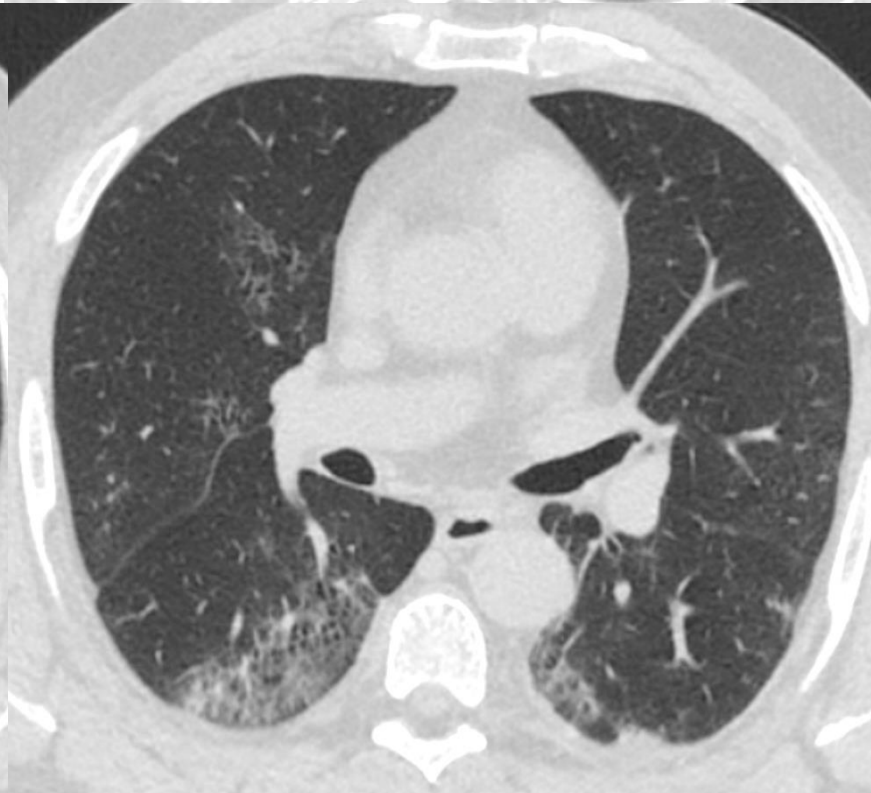
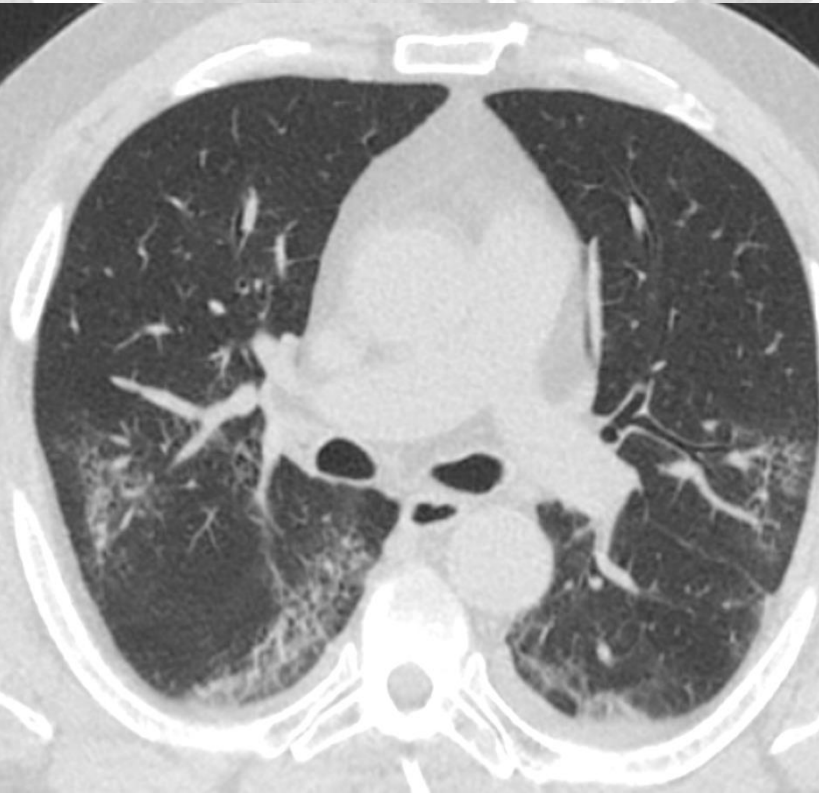
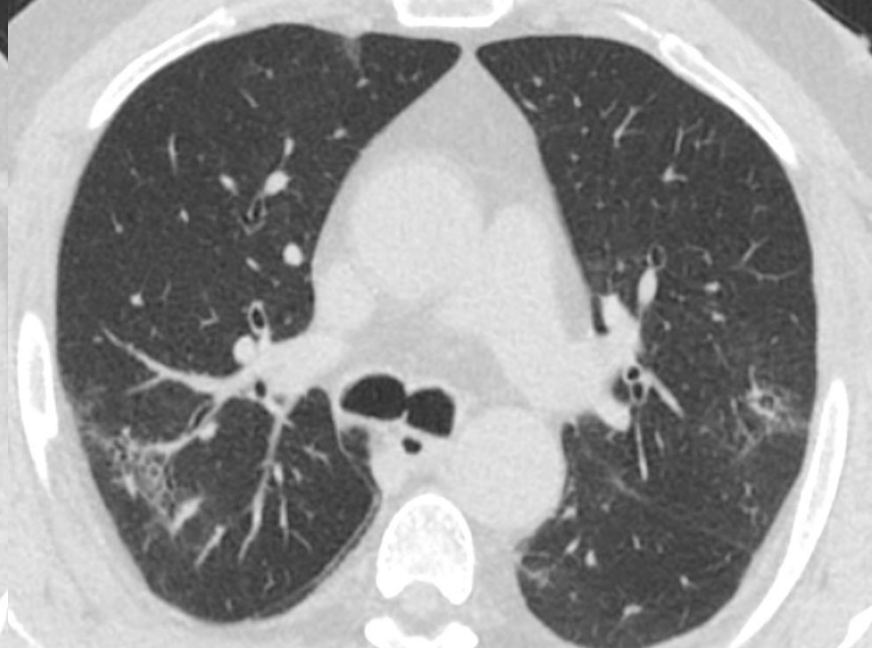

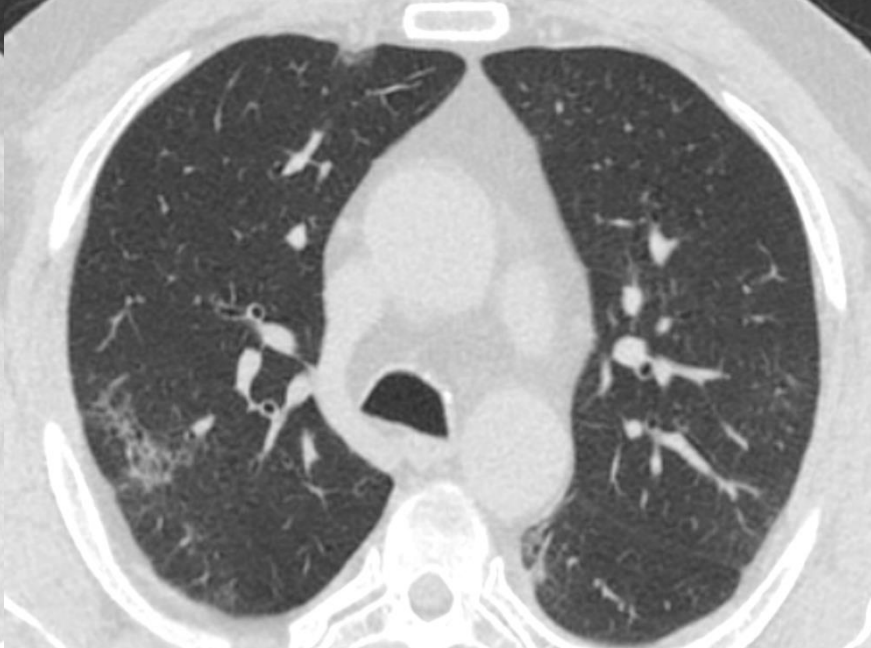
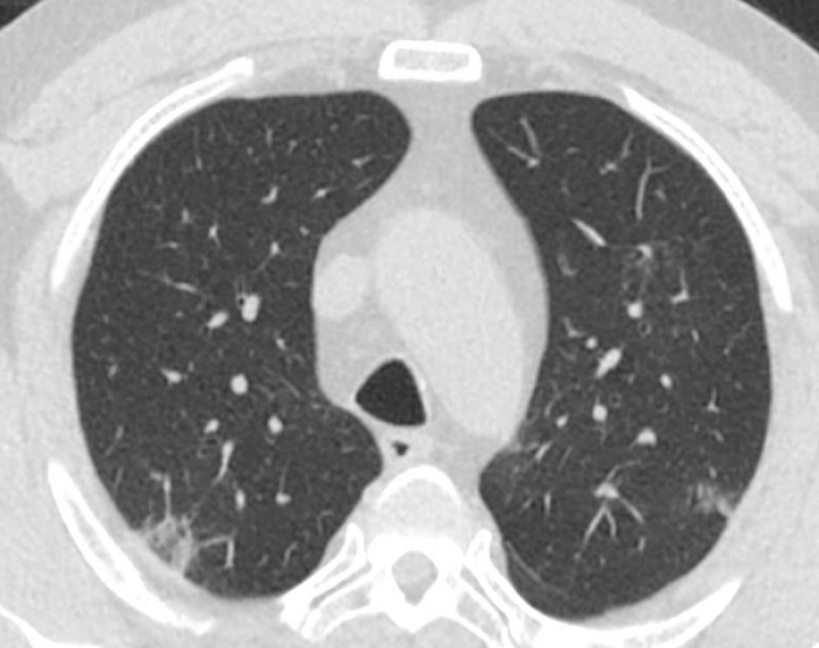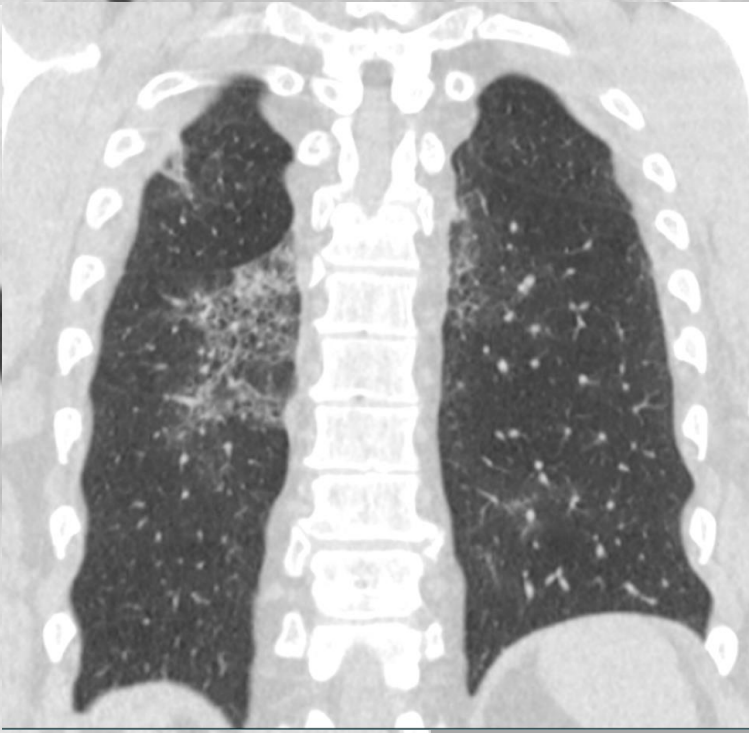
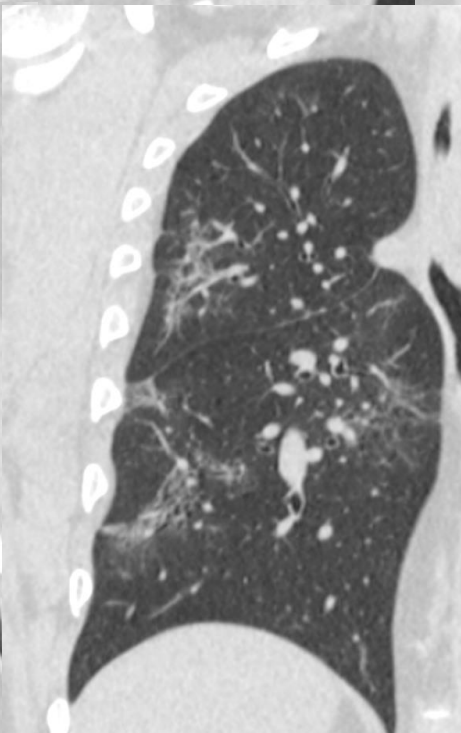
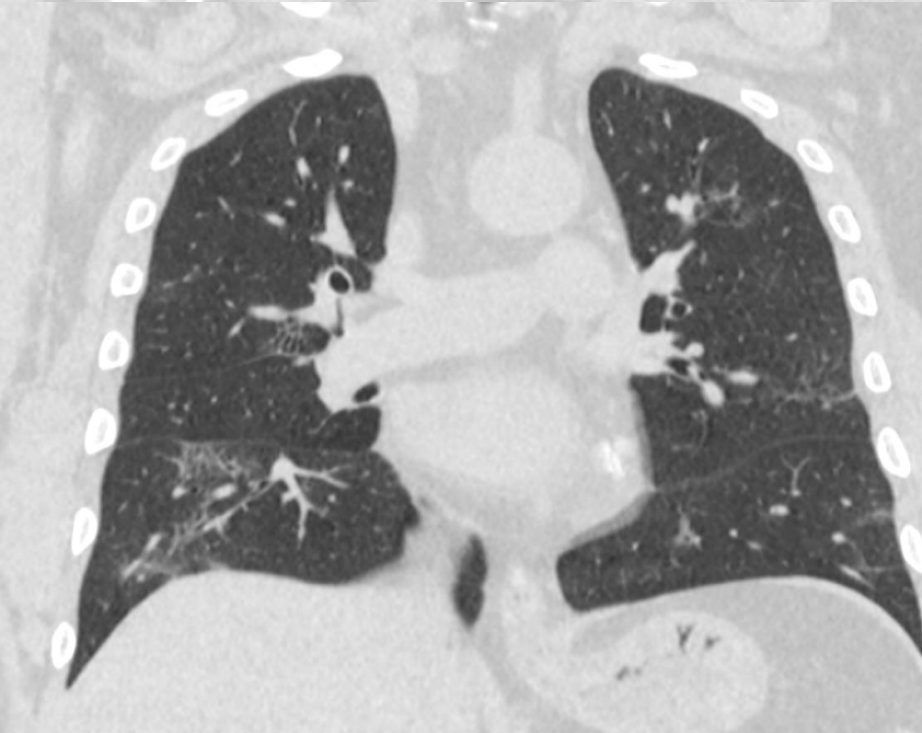
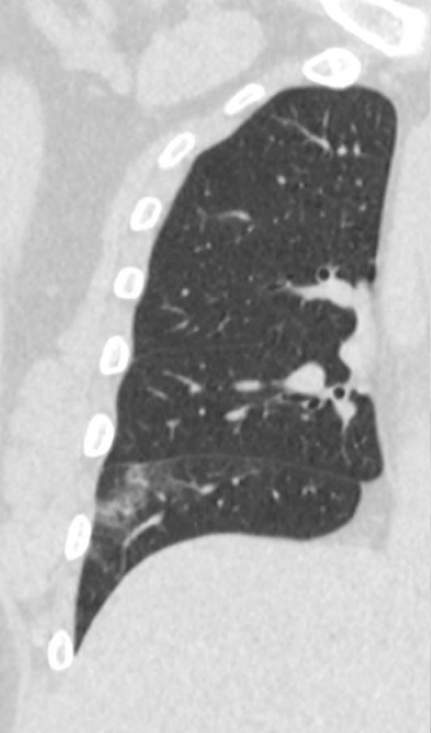
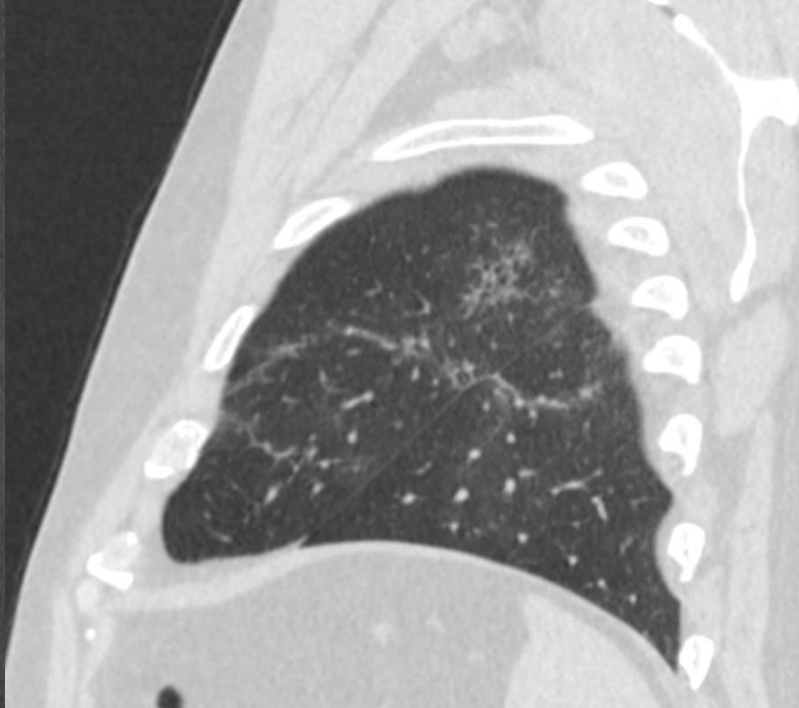
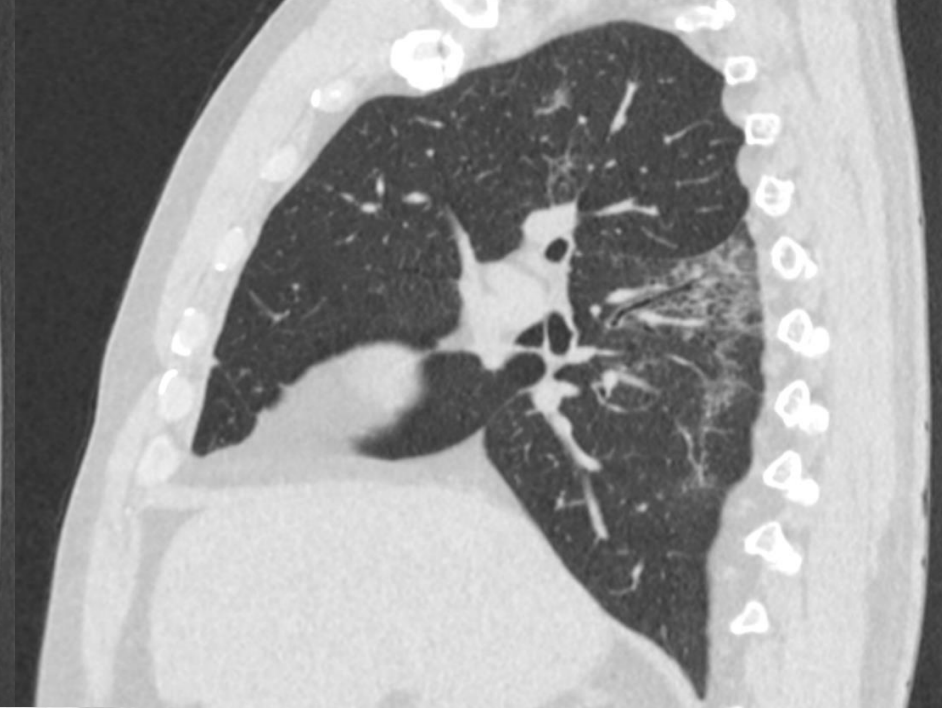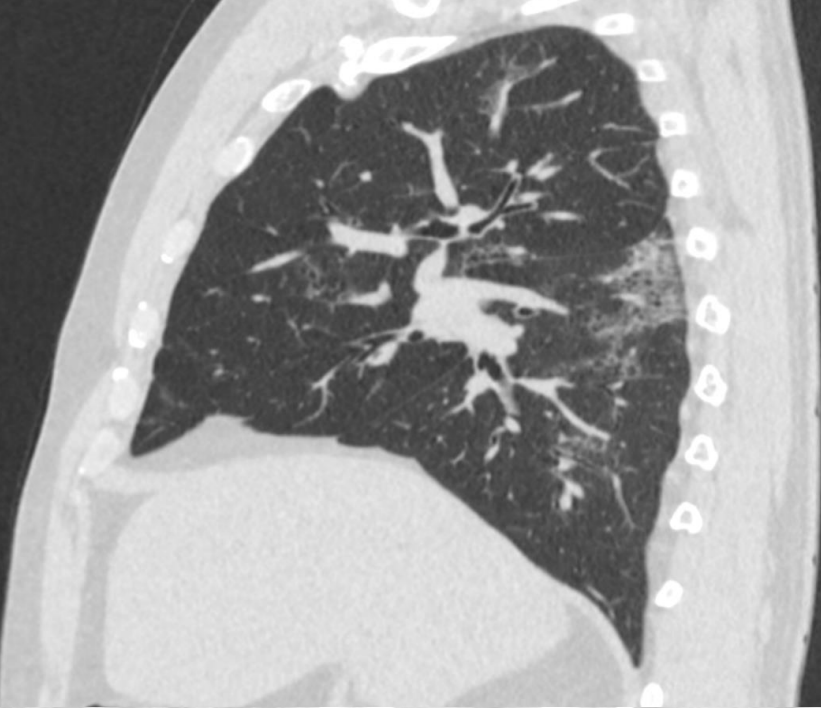KASUISTIKA č. 6 - COVID-19

CASE No. 6 - COVID-19

62-letý muž, teplota 37,8, imunokompromitovaný pacient,
minulý týden návrat ze Španělska, podezření na COVID-19,
později RT-PCR SARS-CoV-2 pozitivní

male 62 yo, 37,8 Celsius gr., immunocompromised, returned
from Spain last week', suspected COVID19, later RT-PCR SARS-
CoV-2 positive





Diferenciální diagnostika COVID-19

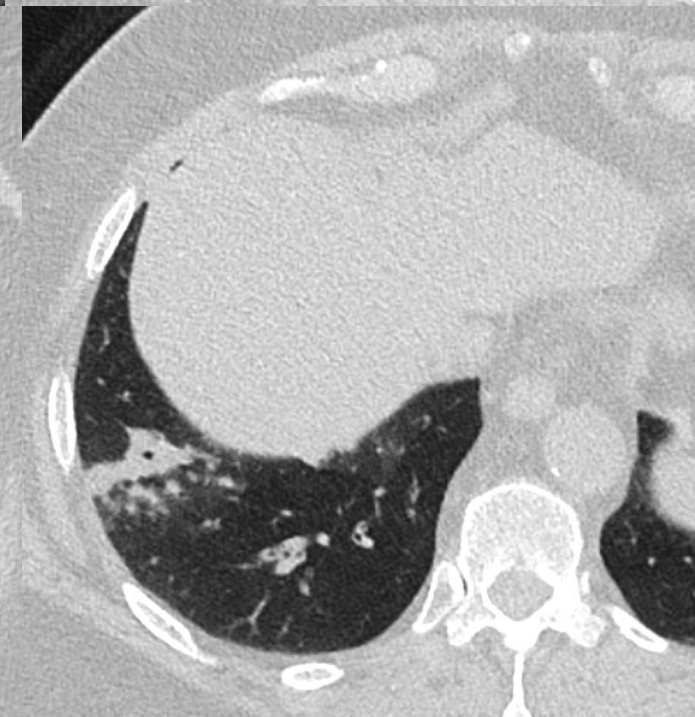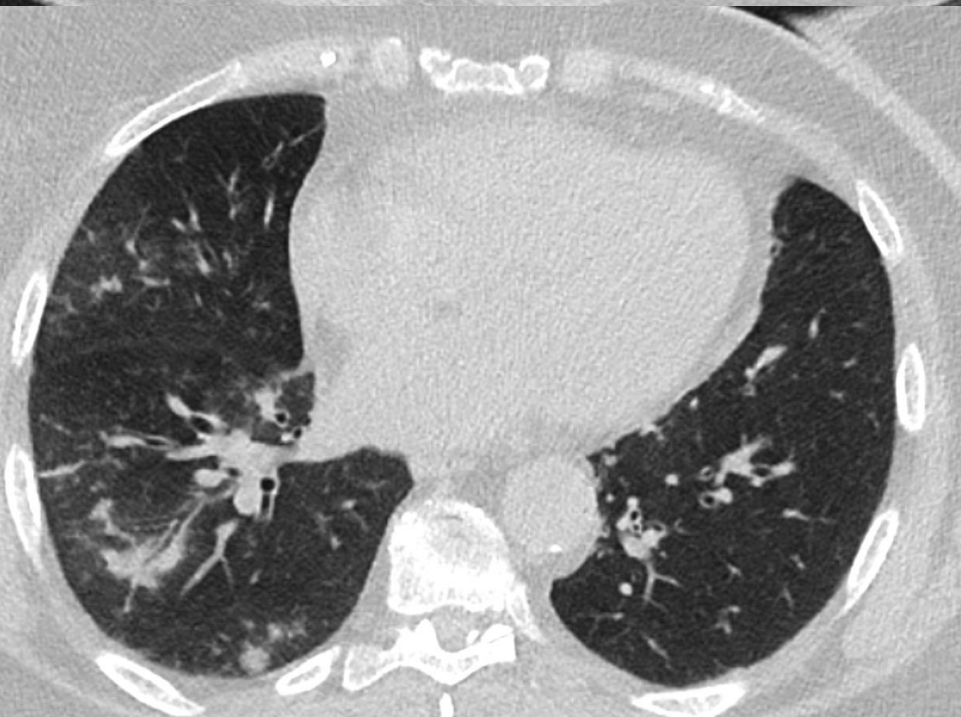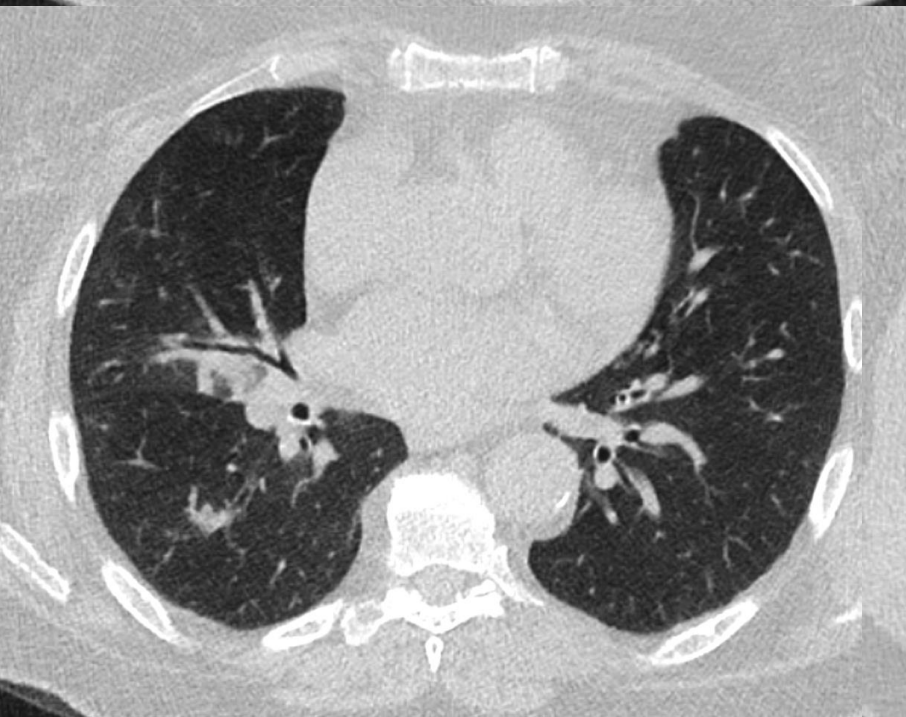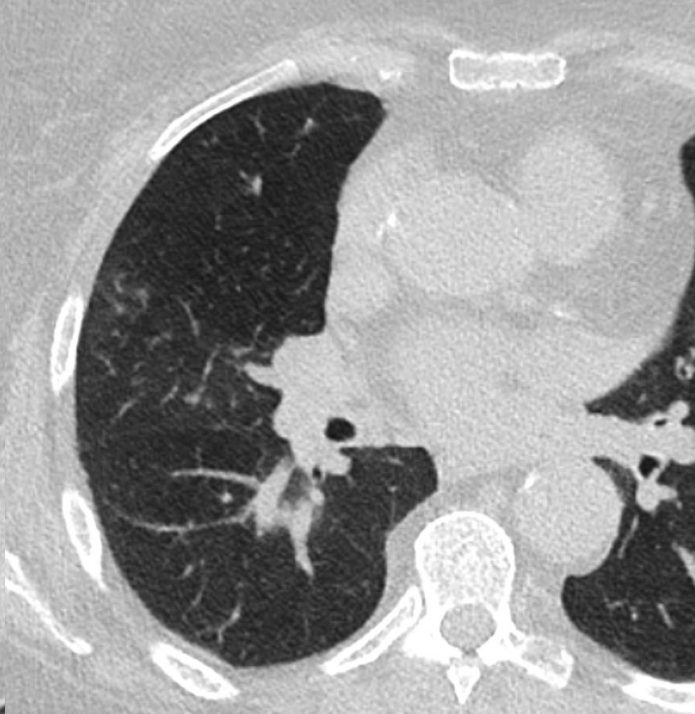
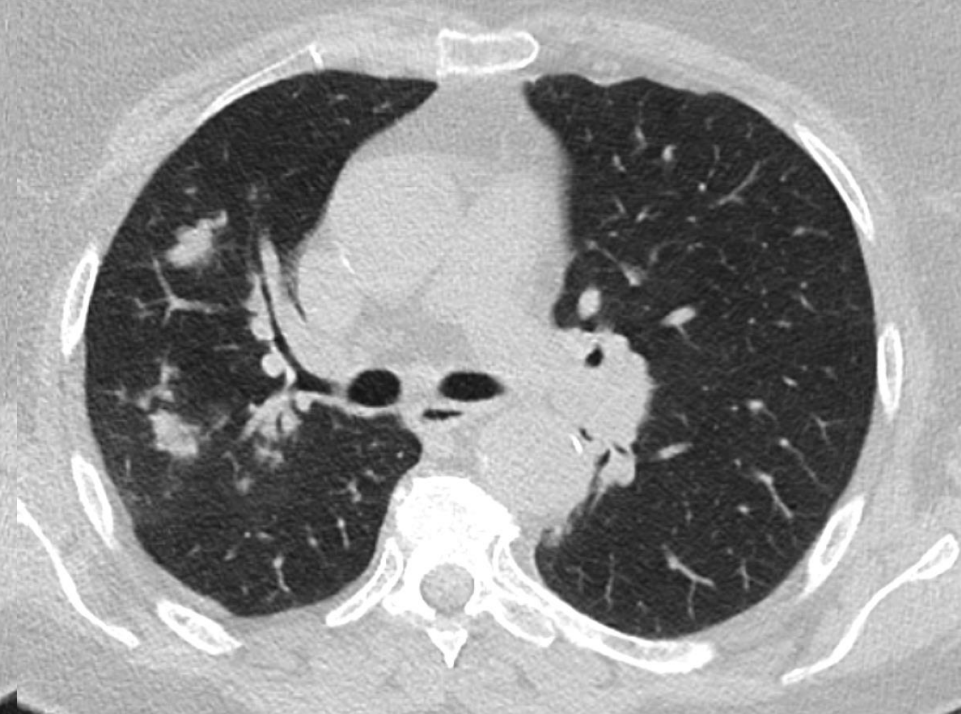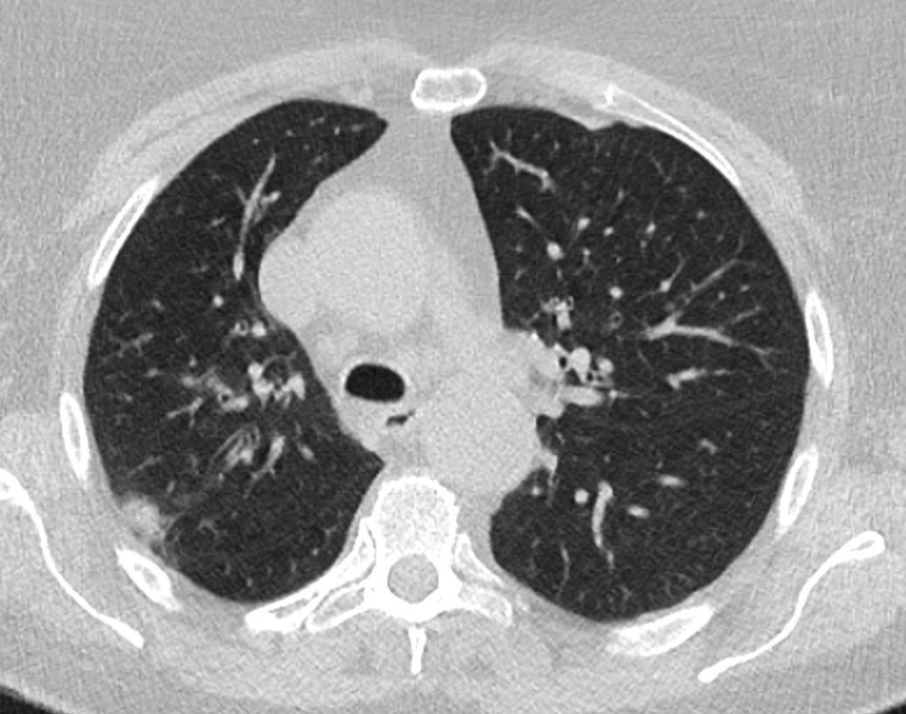
Differential diagnosis of COVID-19

KASUISTIKA č. dif.dg. 1 – bronchopneumonie

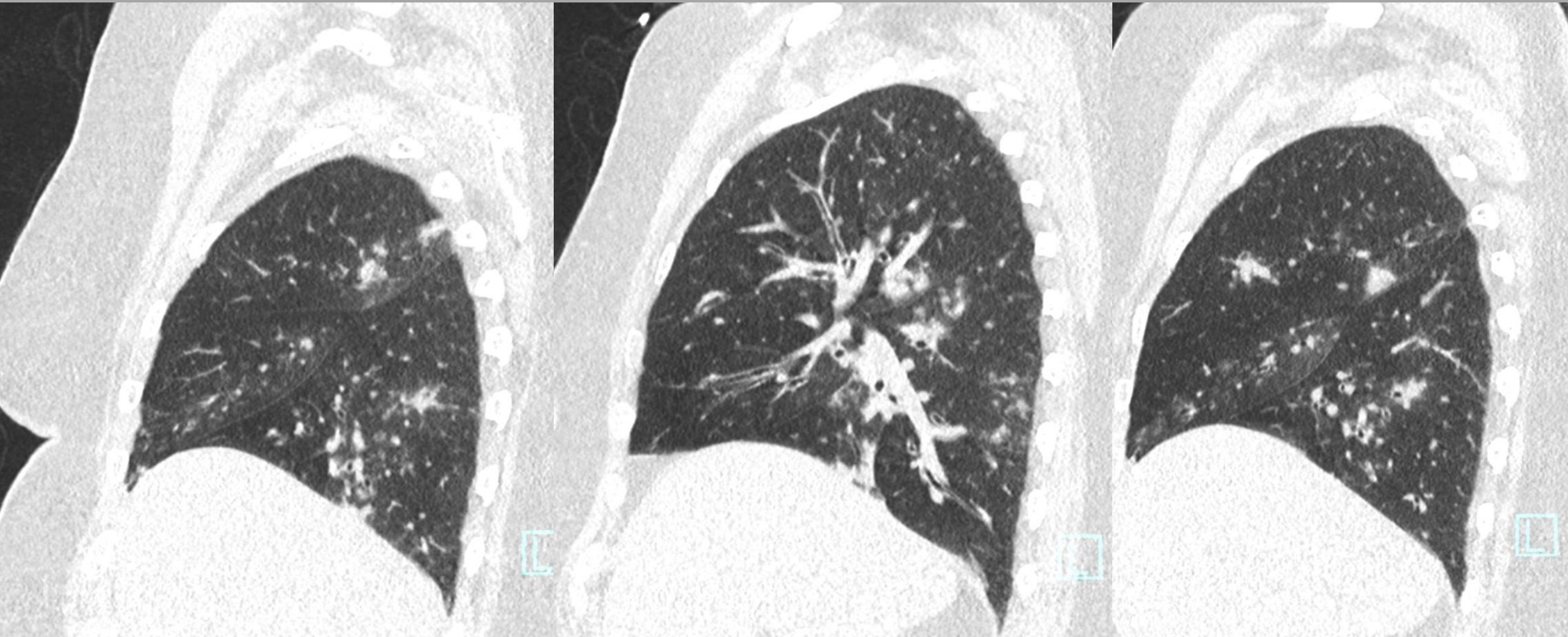
CASE No. Diff.dg. 1 – bronchopneumonia

žena 73 let, diabetes mellitus 2. typu, hypertenze, metabolický syndrom, subfebrilie, kašel, bez cestovatelské anamnézy, nález popsán jako nejistý pro COVID-19, krátkodobá izolace, později RT-PCR SARS-CoV-2 negativní

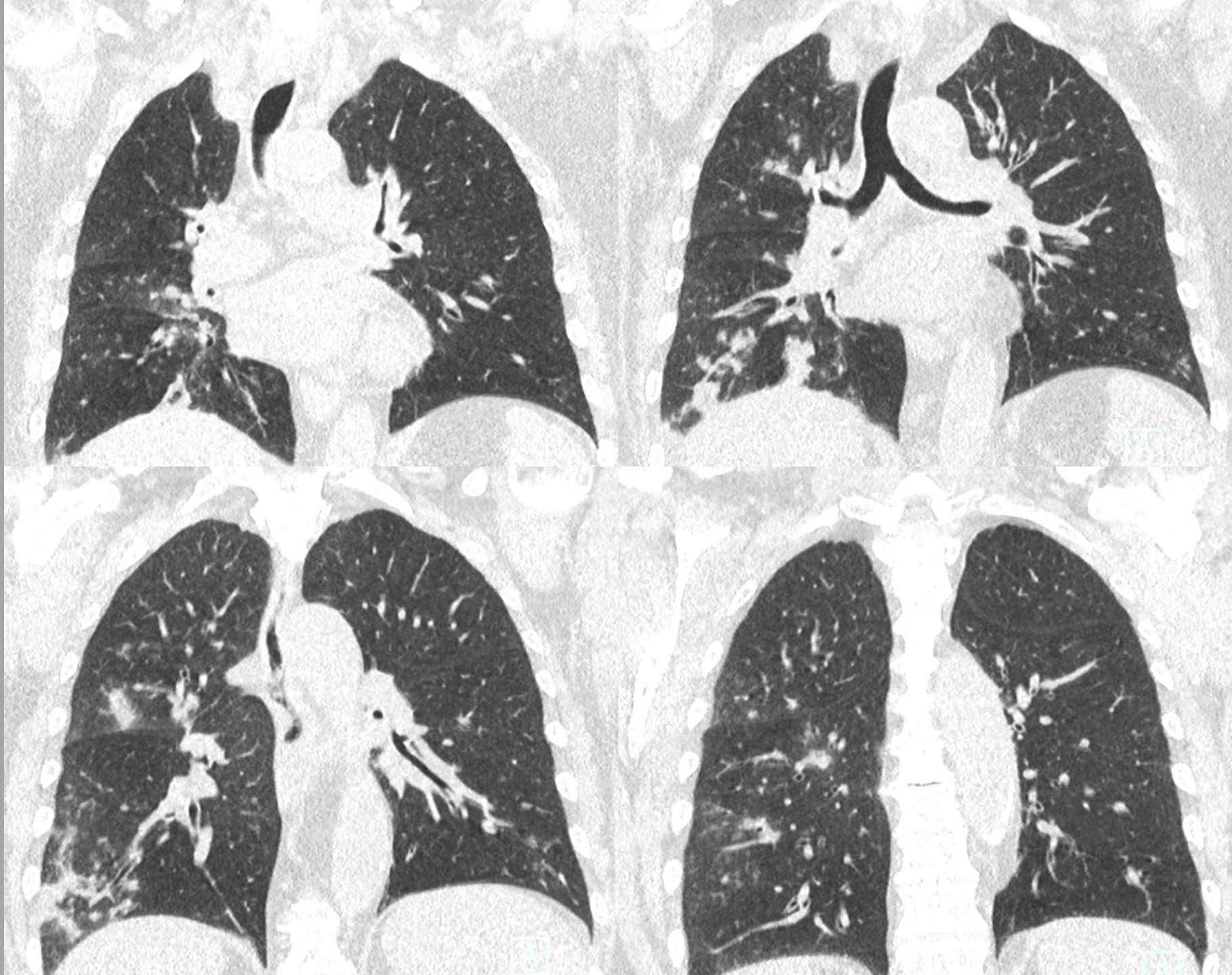
female 73 yo, diabetes mellitus type 2, hypertension, metabolic syndrome, subfebrile, coughing, no traveler history, described as uncertain for COVID-19, later, during short isolation, RT-PCR SARS-CoV-2 negative



Dominující nález jsou peribronchovaskulární distribuce a většinou přítomna konsolidace a ne opacity mléčného skla, také přítomen air-trapping



Peribronchovascular distribution is dominant, mainly consolidation not ground glass opacities, air-trapping also present

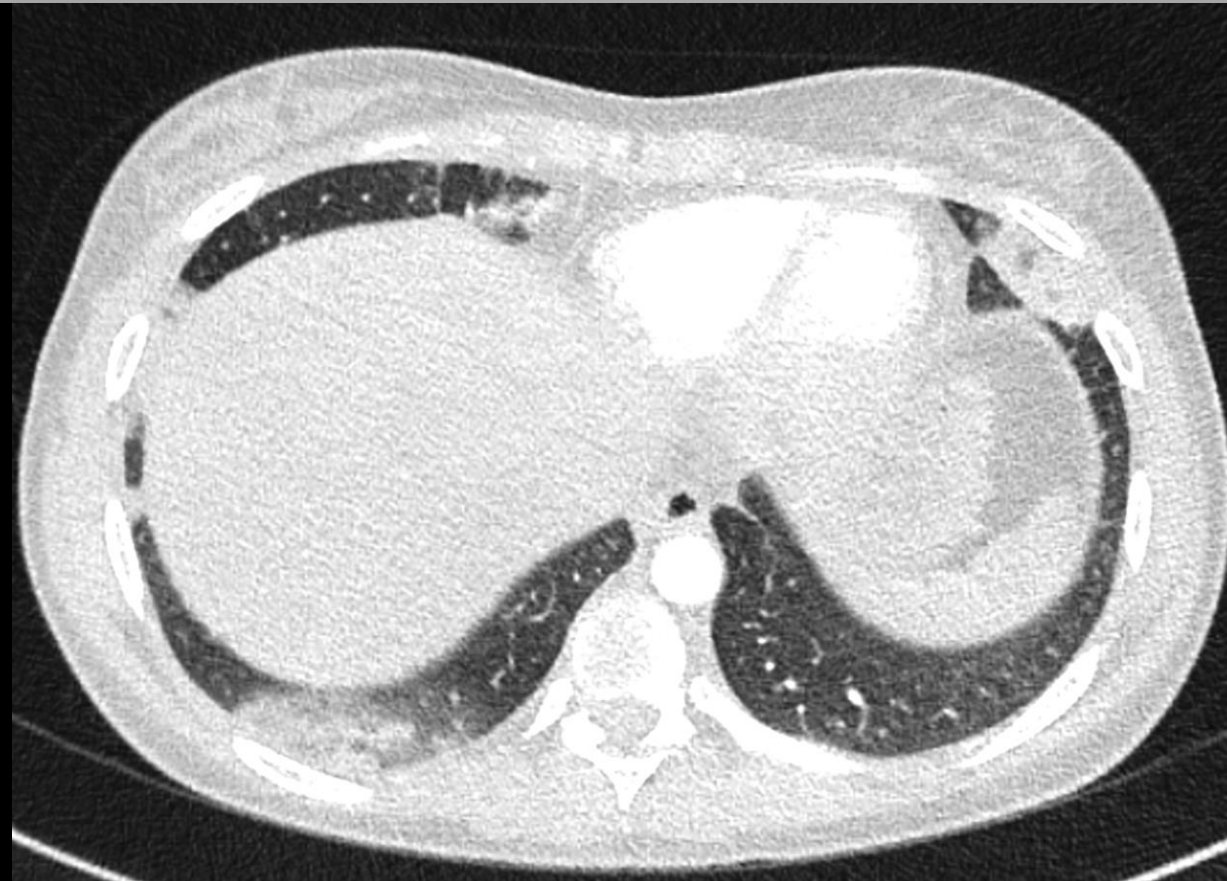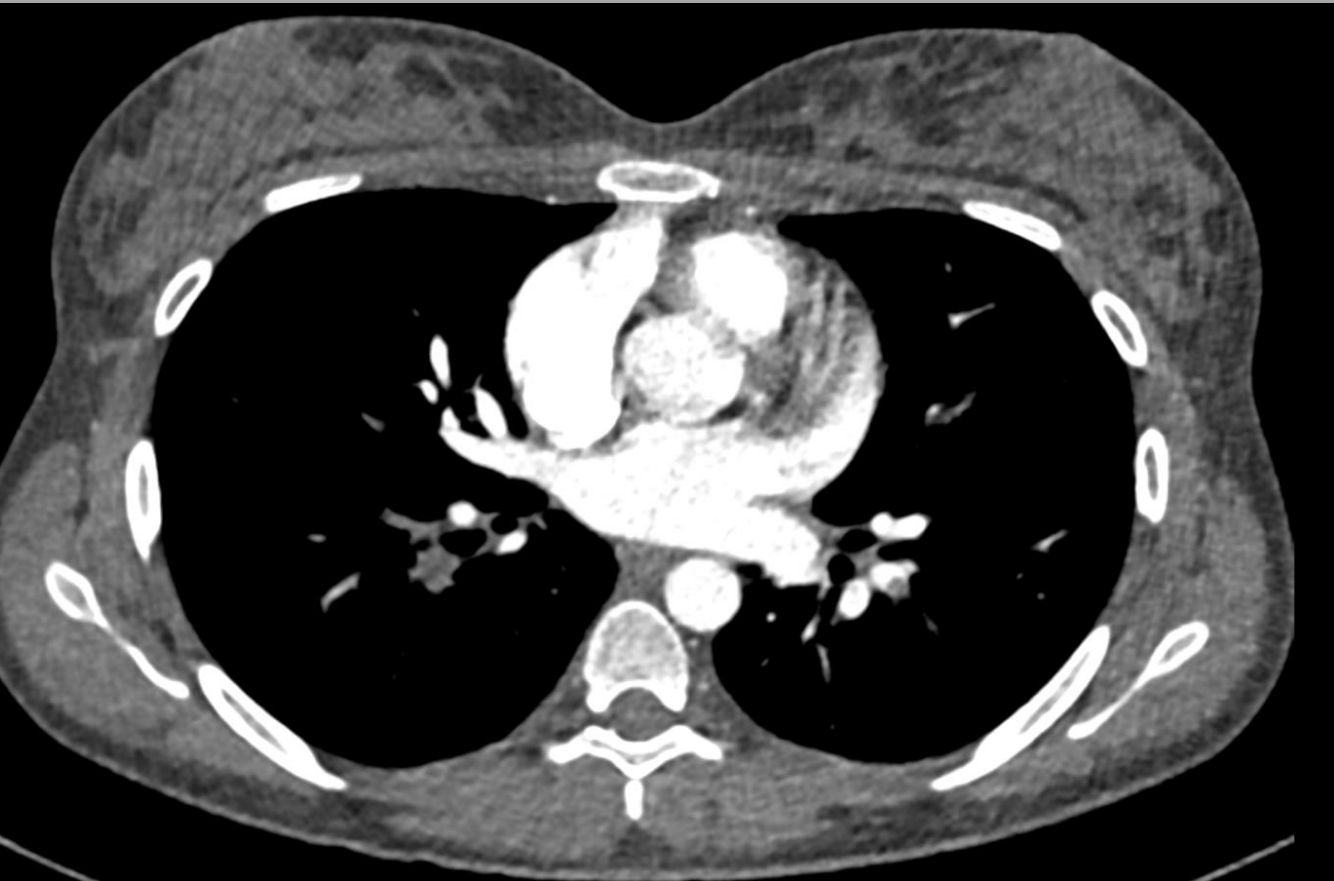


KASUISTIKA č. dif.dg.2 – plicní infarkt

CASE No. Diff.dg.2 – lung infarction

žena 20 let horečka, cizinka, nyní návrat ze Španělska, kašel,
bolest na hrudi, nález popsán jako negativní pro COVID-19
později RT-PCR SARS-CoV-2 negativní

**female 20 yo, fever, foreigner, recently returned from Spain,
coughing, chest pain, the finding descibed as negative for
COVID-19, later, RT-PCR SARS-CoV-2 negative**

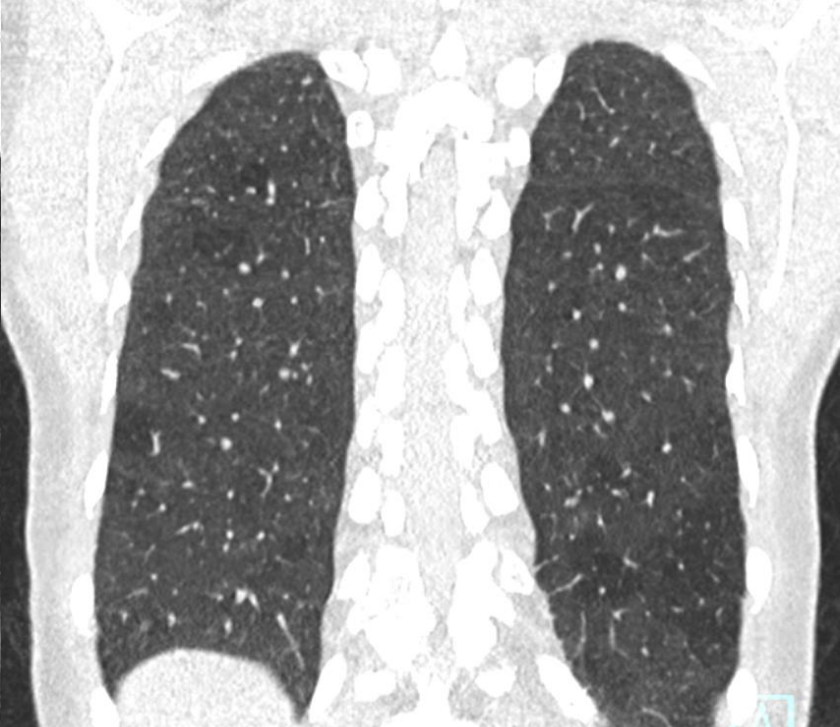
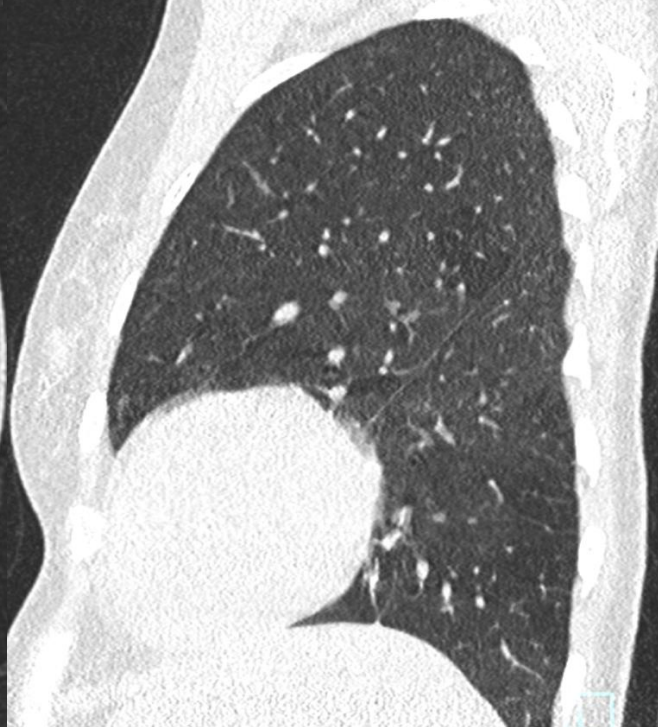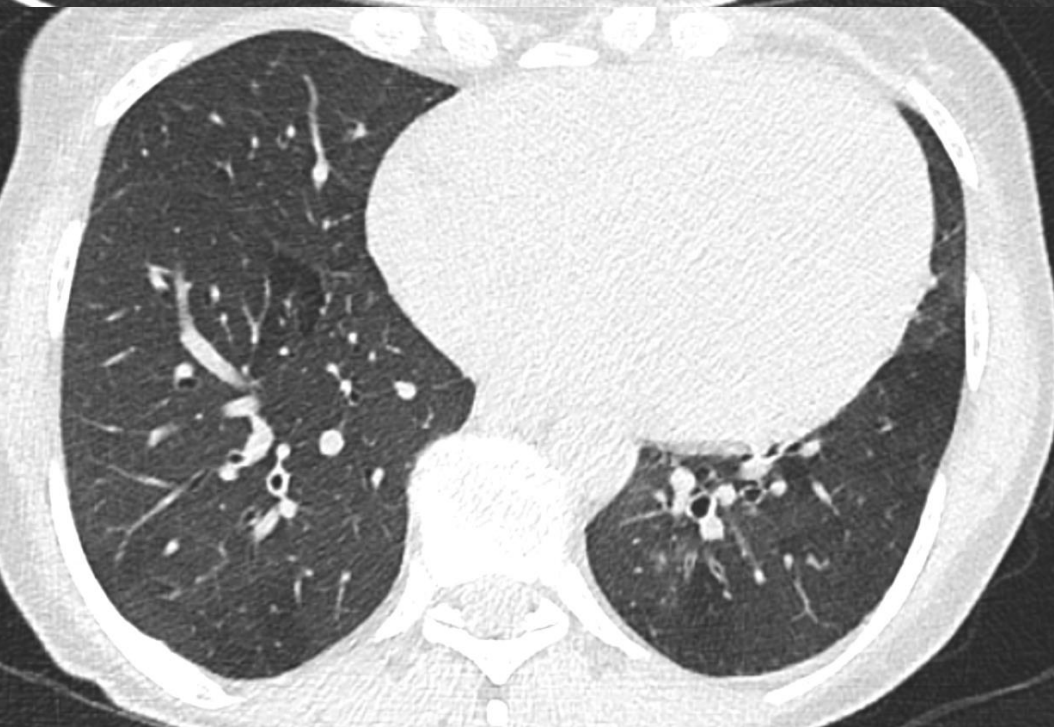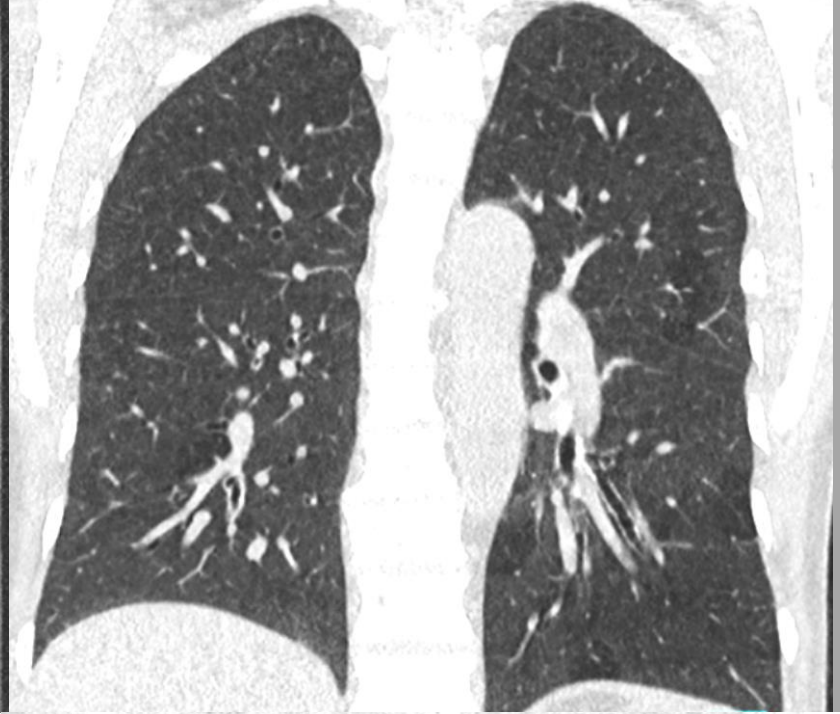
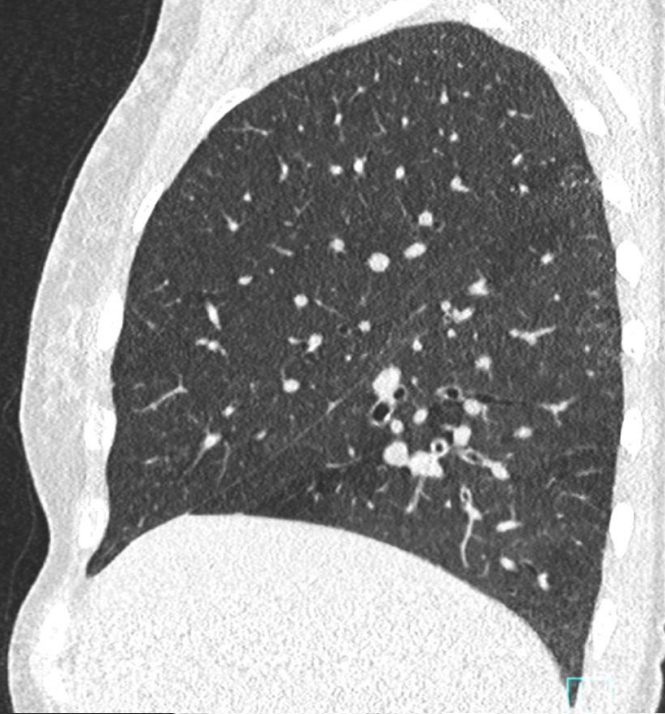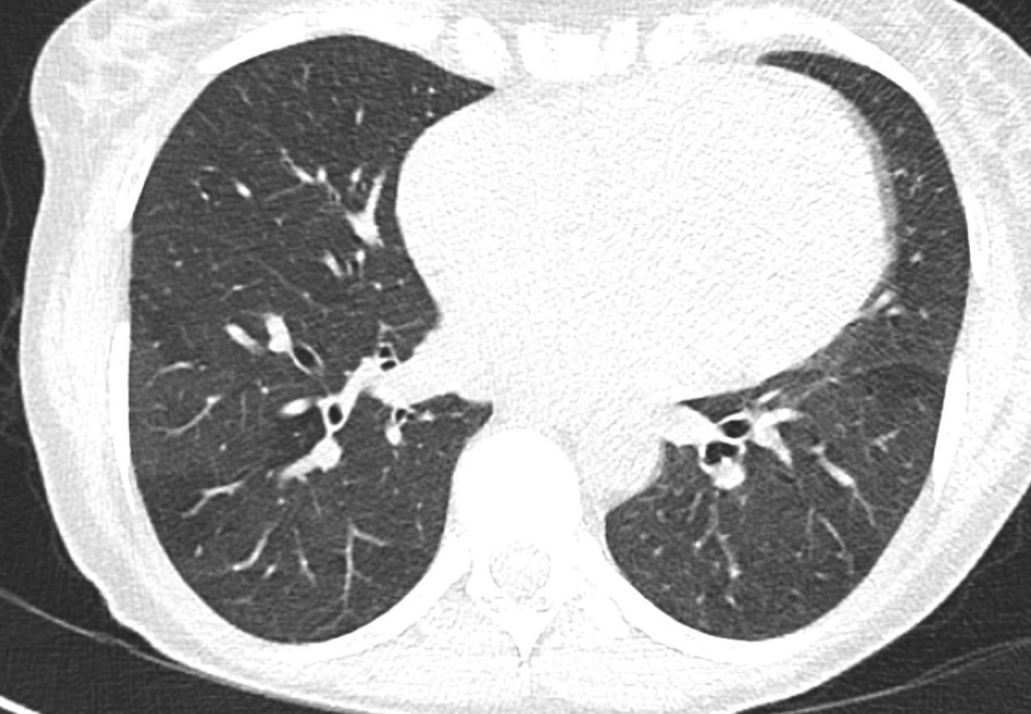


KASUISTIKA č. Dif.dg.3– air-trapping, bronchiolitida

CASE No. Diff.dg.3 – air-trapping, bronchiolitis

**žena 48 let, chronické selhání ledvin, subfebrilie, kašel,
imunokompromitovaná, 3x po graftektomii na dialýze, nález
negativní pro COVID-19, RT-PCR SARS-CoV-2 nebyla provedena**

**female 48 yo, chronic renal failure, subfebrilia, coughing,
immunocompromised, 3x after renal transpantation, following
3x graftectomy, finding of air-trapping, negative for COVID-19,
RT-PCR SARS-CoV-2 was not used**

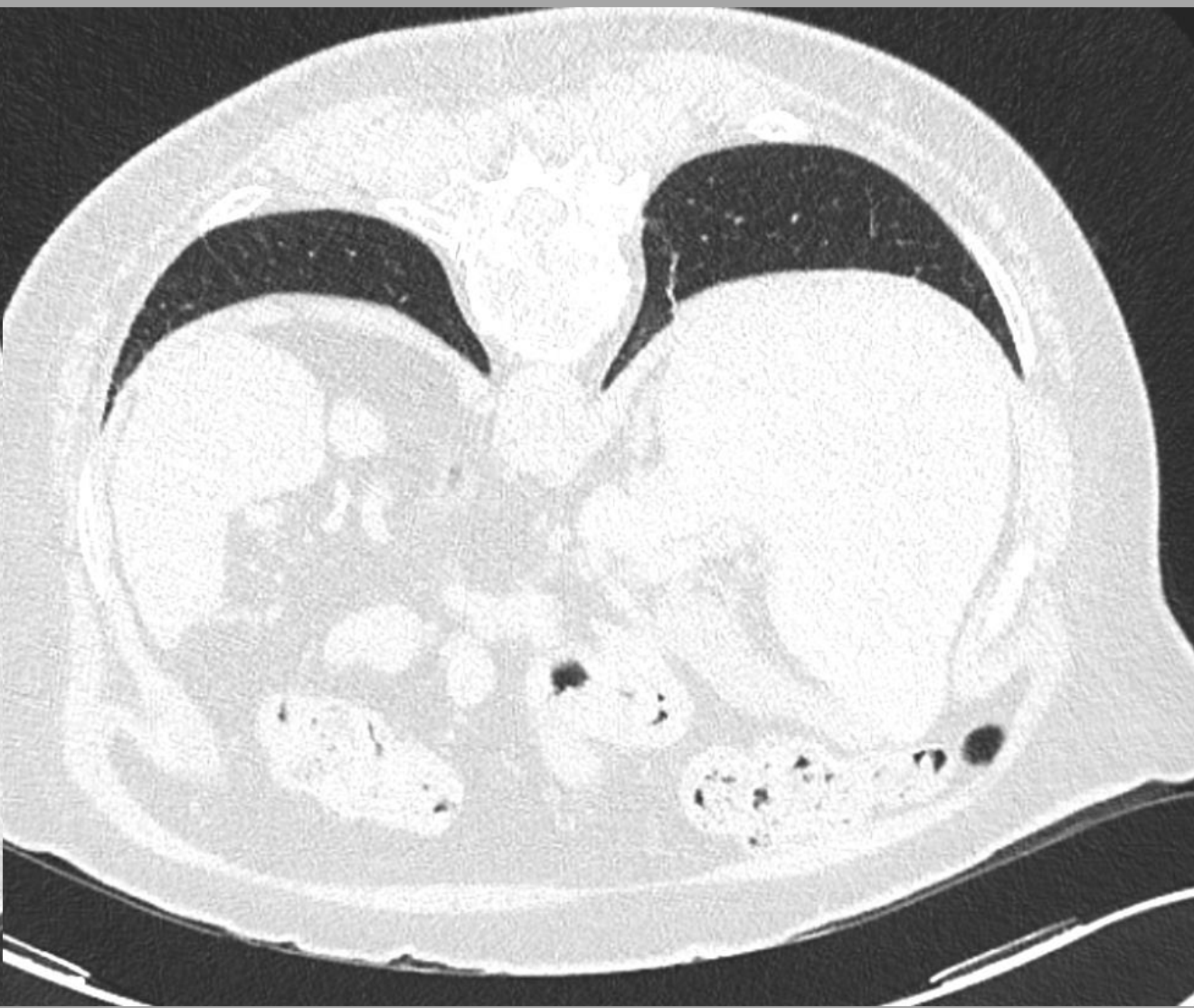
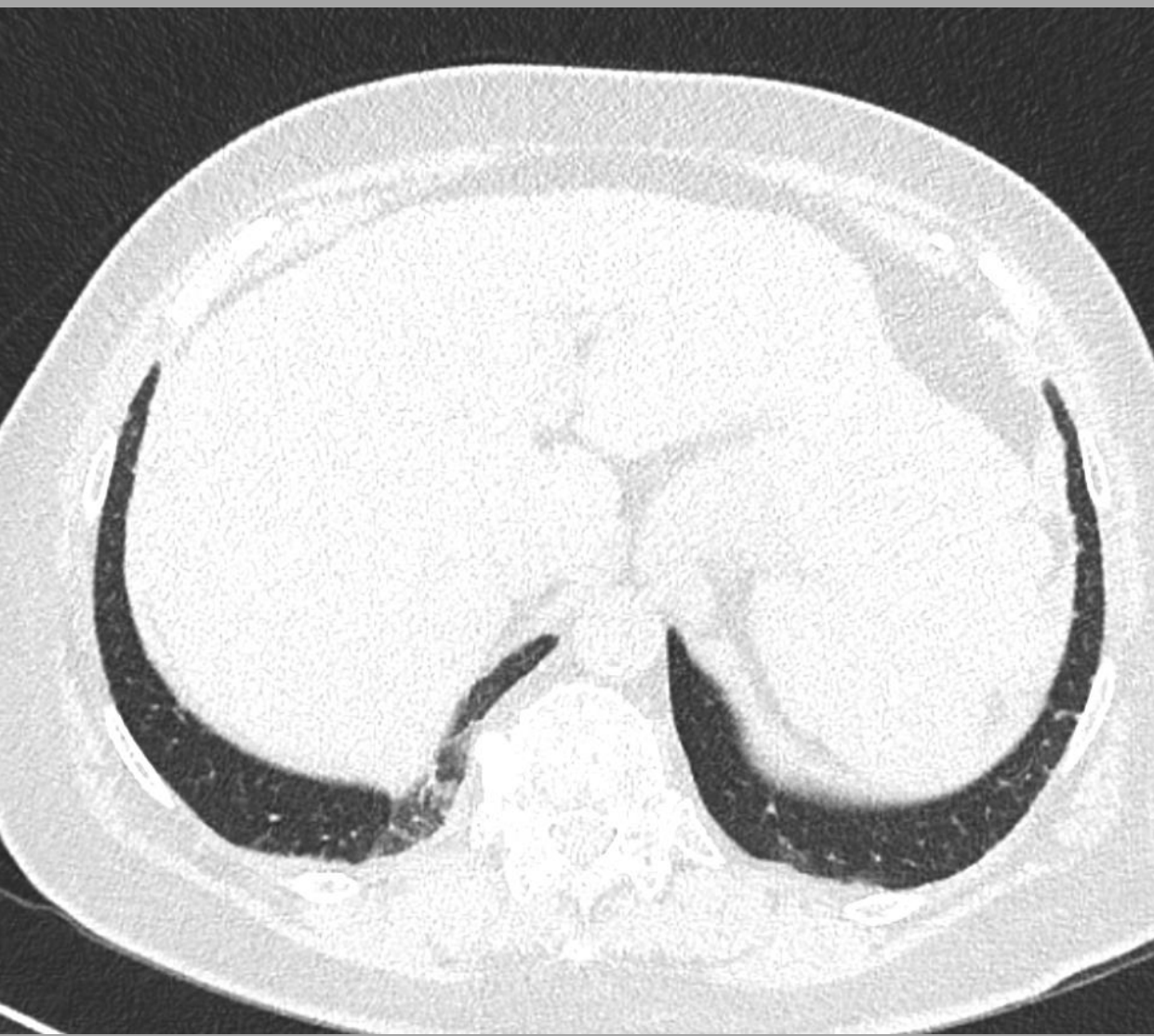


KASUISTIKA č. Dif.dg.4 – gravitační atenuace

CASE No. Diff.Dg.dg.4 – gravitation atenuation

žena 81 let, akutní bolesti zad, týden probíhající respirační infekcí, zhoršení v posledních dnech, nález negativní pro COVID-19, RT-PCR SARS-CoV-2 nebyla provedena – význam skenu na břiše

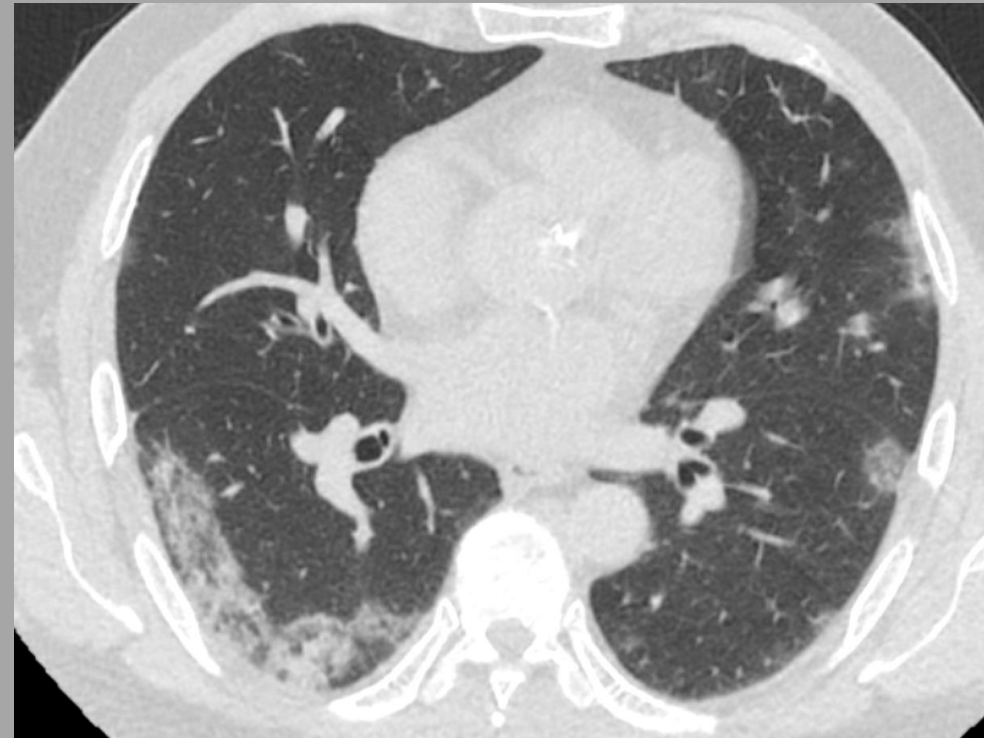
female 81-year-old woman, acute back pain, week-long respiratory infection, worsening in recent days, negative for COVID-19, RT-PCR SARS-CoV-2 was not used – the value of the scans in prone position



CT NÁLEZY V PLICNÍM PARENCHYMU U COVID-19

CT FINDINGS IN LUNG PARENCHYMA IN COVID-19

obrazový přehled/pictorial review



Jiří Ferda, Hynek Mírka, Jan Baxa, Petr Rajchman, Alena Vondráková, Jana Váchalová

FAKULTNÍ NEMOCNICE PLZEŇ /UNIVERSITY HOSPITAL PILSEN- CZECH REPUBLIC